

Mycobacterium ulcerans Infection¹

(With Comments on Pathogenesis)

Daniel H. Connor, M.D. and H. Fletcher Lunn, F.R.C.S.²

In 1962, as a member of the Geographic Pathology Division of the Armed Forces Institute of Pathology, I (D.H.C.) was assigned to Makerere College Medical School, Kampala, Uganda. During two and one half years there I studied a number of the local diseases. One of the most challenging of these was the mycobacterial necrotizing ulcer. In collaboration with Mr. Lunn and others⁽⁵⁾ it was possible to study the

epidemiologic, clinical and pathologic aspects of this remarkable disease. Although necrotizing ulcers have been seen in Uganda for many years, the causal role of *Mycobacterium ulcerans* has only recently been recognized, thanks to the pioneer work of MacCallum and associates in Australia⁽⁷⁾ and the later reports of Janssens and other Belgian scientists working in the Congo⁽³⁾.

Mycobacterium ulcerans infection causes a deep expanding painless ulcer, which may grow to enormous size. In extreme cases its relentless progress was checked only by amputating the affected extremity. The first report from Uganda⁽¹⁾ recognized a concentration of cases in Buruli County, a sparsely populated region along the upper Nile. It is now recognized, however, that in Uganda this infection attacks almost ex-

¹Presented by Dr. Connor. This work was supported in part by a research grant, Project Number DA-MD-49-193-63-G101, from the Medical Research and Development Command, U. S. Army, Washington, D. C.

²The authors are respectively: Pathologist, Geographic Pathology Division, Armed Forces Institute of Pathology, Washington, D. C. and Makerere Medical School; and Senior Lecturer, Department of Surgery, Makerere Medical School, Kampala, Uganda.



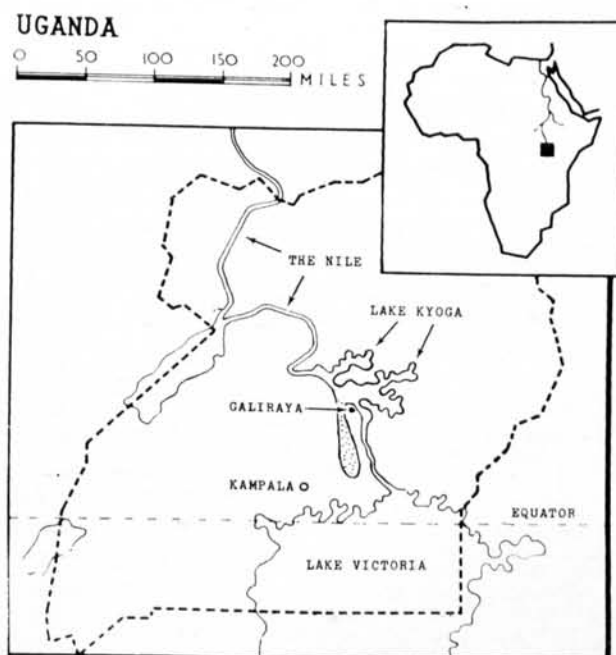
FIG. 1. *Mycobacterium ulcerans* ulceration of the leg of a 7 year old boy who lived in swampy terrain near the Victoria Nile. Treatment consisted of extensive and repeated debridement and skin grafting. The boy now has a normally functioning leg. AFIP Neg. 65-2976.

clusively those people living along the Nile and around Lake Kyoga. Fortunately most of these areas are thinly populated and yield very few patients. In one community near a ferry crossing, however, the population density is high, and mycobacterial ulceration is so common that only severe cases can be admitted to the local hospital for in-patient care⁽⁵⁾. Figure 1 shows an advanced case with extensive tissue destruction and skin loss. At this stage, care-

ful and prolonged surgical management offers the only hope of saving the extremity. Fortunately the results were good in this case, but a critically needed hospital bed was occupied for six months.

In the 38 cases of this mycobacterial infection that we studied histopathologically, all but one had an ulcer when first seen. In this exception, the patient was brought in before the ulcer had formed, and this gave us the opportunity to study the infec-

FIG. 2. The patient lives at Galiraya, a small village almost surrounded by water. This area is thinly populated (less than 50 persons per square mile) and yet 13 people from this peninsula, including the boy's mother and sister, have had mycobacterial ulcers in the past. So far, virtually all proven cases have come from homes situated within a few miles of the river Nile or Lake Kyoga. Uganda's population is concentrated in a broad zone along the north shore of Lake Victoria, but this is not an endemic area.



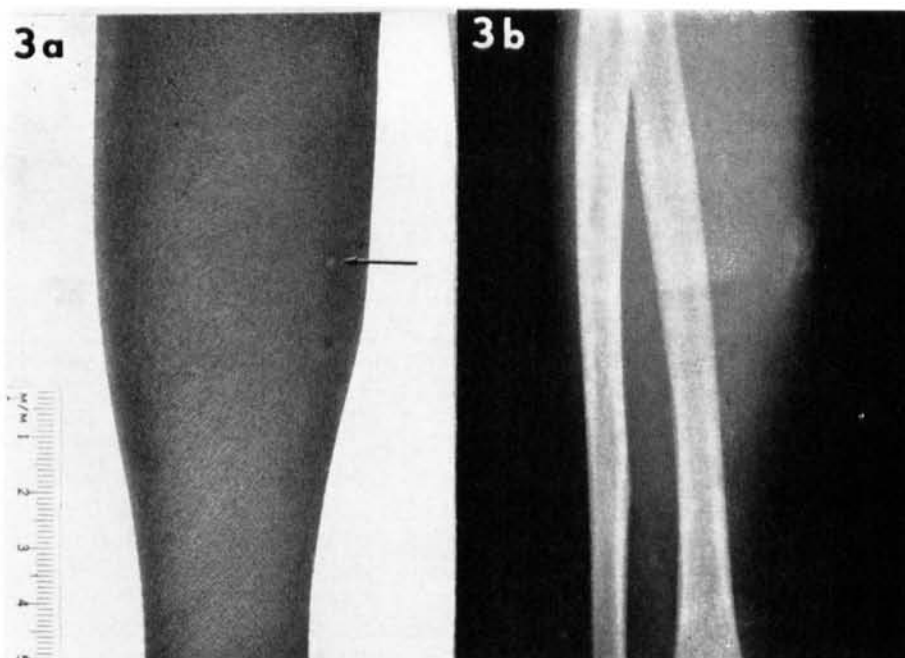


FIG. 3a. The lesion (a 5 x 3 cm. area of subcutaneous induration) can be recognized as a slight protrusion along the lateral border of the mid-forearm. The involved area was hard, moved freely on the deep tissues, and was sharply demarcated on palpation. A round vesicle 2 mm. in diameter is situated over the center of the indurated area (arrow). It is pale, circular, and surrounded by a hyperpigmented halo. AFIP Neg. 65-3139.

FIG. 3b. A roentgenogram reveals calcium in the indurated area. AFIP Neg. 65-3139.

tion at an early stage, before the histopathologic picture was complicated by secondary infection and native treatments. Our observations gave insight into the pathogenesis and raised some fundamental questions about the nature of this peculiar organism.

A nine-year-old African boy was brought to us by Dr. I. Kafero, his family doctor. He was the son of a schoolmaster at Galiraya, a village located at the extreme northern tip of the Bugerere peninsula in Uganda. This village, located on a narrow tongue of land 50 miles long and 10 miles wide, is almost surrounded by water (Fig. 2). Although Galiraya has a population of less than 50 inhabitants per square mile, 13 residents of this area, including the patient's mother and sister, have had mycobacterial ulcers during the past four years.

The patient was admitted to Mulago Hospital, Kampala, on 30 May 1963, with a firm, raised swelling of his right forearm, which had been noticed five months previously. It had begun as a small raised

papule, but there had been no ulceration or suppuration. The surrounding tissues gradually became firm and, when first seen in May 1963, the indurated area measured 5 cm. x 3 cm. The lesion had a well defined border, could be moved freely on the deep tissues, and resembled closely the lesion of subcutaneous phycomycosis⁽¹⁾, except for the fact that there was a small round vesicle 2 mm. in diameter over the center of the indurated area (Fig. 3a). Physical examination revealed no enlargement of regional lymph nodes and no other significant abnormality.

A roentgenogram of the right forearm disclosed a mottled area of calcinosis in the subcutaneous tissues, the location of which corresponded to the central part of the indurated area (Fig. 3b). It was important to differentiate between subcutaneous phycomycosis, a mild nonulcerating infection that may occur on the extremities of children in Uganda, and *Mycobacterium ulcerans* infection, which, if not treated promptly, causes progressive ulceration.

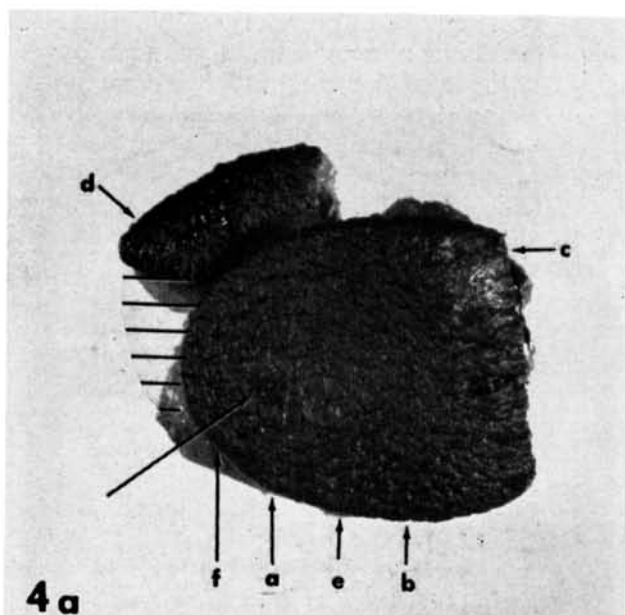


FIG. 4a. The excised specimen consisted of two fragments. The straight edge on the right is the margin of the earlier biopsy. The cross-hatched area was cultured and the letters refer to blocks taken in the same axis as the arrows. The long arrow points to the vesicle. Colonies of mycobacteria were centered in block **a** and a few colonies were found in sections from the central aspects of the blocks **e** and **f**. Sections from blocks **b**, **c**, **d**, and from the peripheral side of **f** revealed noninflammatory necrosis, but no acid-fast bacilli, and the portion cultured yielded no mycobacteria. See Figure 7 for a diagrammatic representation. $\times 2$. AFIP Neg. 65-4556 (2).

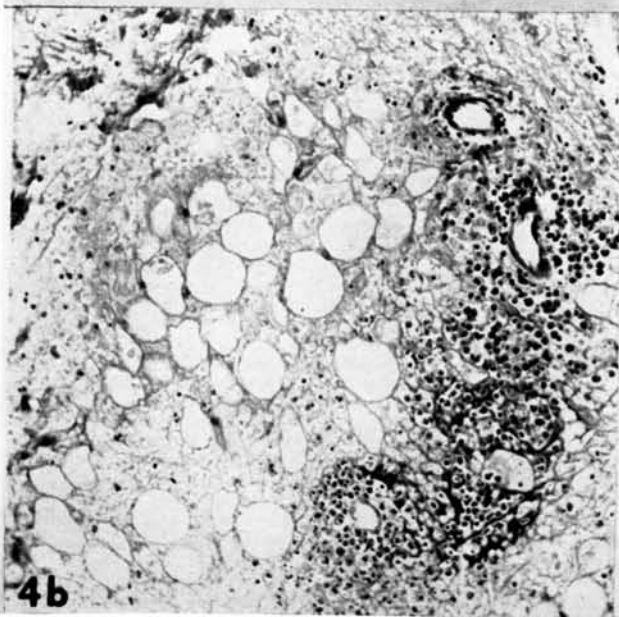


FIG. 4b. In this first biopsy the most prominent change is necrosis of adipose tissue. A ghost outline of swollen fat cells remains, but cell nuclei and the intercellular capillary circulation have vanished. Inflammatory cells were not prominent, but occasional accumulation, as seen here (eosinophilic leucocytes, lymphocytes, plasma cells, and polymorphic leucocytes) were found about small vessels. Giemsa stain. $\times 145$. AFIP Neg. 65-1417.

Without delay, therefore, a biopsy was performed. This was taken from the periphery of the lesion at the junction of the indurated and normal tissues. Because of the possibility that this was an *M. ulcerans* infection, the patient was given phenazine (Geigy, B.663), 100 mgm. twice a day, for six days, preoperatively, as recommended in a previous report⁽⁶⁾, and this dosage was continued after operation in an attempt to prevent spread or recurrence.

Eight days after biopsy, the entire lesion

was excised and the open area covered with split skin grafts. It healed within a week, but phenazine was continued for one month, after which time the boy returned home. The excised area has remained firmly healed without evidence of recurrence.

PATHOLOGY

The first biopsy included skin and subcutaneous tissue. Grossly the surface was

normal, but at one end the attached fat was opaque and indurated. Microscopically, this was a necrotic zone, devoid of functioning capillaries, and it involved the lower dermis and the subcutaneous adipose tissue. Swollen necrotic cells were separated by amorphous eosinophilic material. The cell nuclei had vanished, but a faint or "ghost" outline of previously viable fat cells and other structures remained. Inflammatory cells were not conspicuous, but occasional perivascular collections of eosinophilic leucocytes, lymphocytes, plasma cells, and rare polymorphic neutrophils were evident (Fig. 4b). There were no acid-fast bacilli in the sections, but on the basis of this peculiar necrosis of the panniculus a provisional diagnosis of *Mycobacterium ulcerans* infection was made.

The excisional specimen taken eight days later was composed of two fragments. Figure 4a shows the orientation of these fragments, the margin of the first biopsy, the vesicle, and the portion sent for culture. The surface, except for the vesicle and suture marks from the first biopsy, was normal, but the attached subcutaneous tissues were woody-hard and cut with a grating sensation. The cut surface was opaque, and streaked yellow and white (Fig. 5). Microscopically, there was an ovoid region of necrosis centered in the subcutaneous fat measuring 2.5 cm. x 2.0 cm. The necrotic tissue was intensely eosinophilic and virtually devoid of inflammatory cells, nuclei, and capillaries. A

ghost outline of previously viable cells and structures remained toward the periphery of the necrotic zone, but in the center most of the structure was lost. The necrosis extended upward through the corium and penetrated the epidermis where the vesicle had formed (Fig. 6a). Most remarkable of all, was the lack of any significant vascular or inflammatory cell response, even at the junction of the viable and necrotic tissues.

Sections stained for acid-fast bacilli revealed colonies, clumps, and individual mycobacteria, concentrated in the center of the necrotic zone. In the hematoxylin and eosin-stained sections (Fig. 6b), they could be seen with the naked eye. Sections taken from blocks e and f (Fig. 4a), on the side toward the vesicle, contained scattered mycobacterial colonies, but sections from their outer aspects contained none. Similarly, blocks b, c, and d, as well as the first biopsy, contained no mycobacteria, but each of these fragments had areas of fat necrosis. The specimen sent for culture yielded no mycobacterial growth. The portion cultured was taken from the periphery only, but at that time we had no idea that masses of organisms were concentrated in the center of the lesion. This negative culture from the periphery, however, supports our observation that the organisms are confined to the center of the necrotic zone, and the other clinical and pathologic findings leave no doubt that this is a *Mycobacterium ulcerans* infection. Blocks from the periphery of the specimen (c, d, and the first

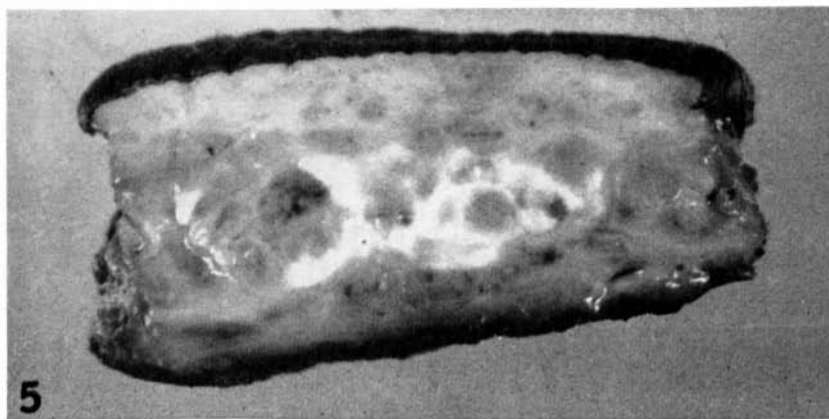

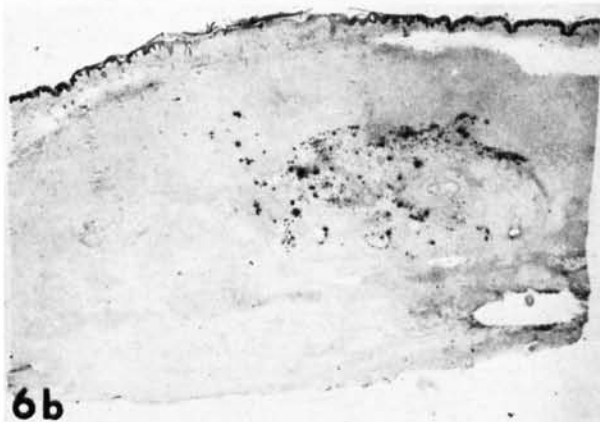


FIG. 5. This is the cut surface at b, (Fig. 4a). The subcutaneous fat was woody-hard and cut with a grating sensation. The surface was mottled yellow and white. $\times 4$. AFIP Neg. 64-2989.



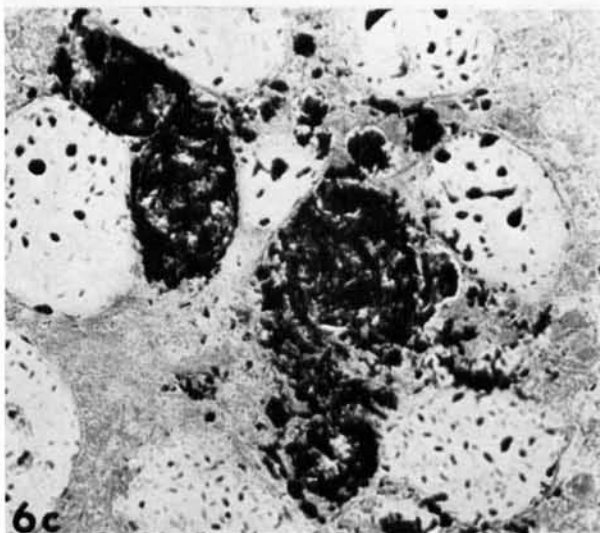
6a

FIG. 6a. A photomicrograph of a section prepared from block **a**. The necrotic area extends to both lateral margins and to the depth of the specimens. No tissue has been trimmed away, and the margins thus represent the limits of the excision. A ghost outline of fat cells, lobules, vessels, nerves, and collagen bundles remains at the periphery of the necrotic area. The corium is involved over the center and the necrosis has reached the epidermis where the vesicle is forming. The mycobacterial colonies are slightly basophilic and can be seen in the center of the necrotic zone. No significant vascular or cellular inflammatory response is evident. Hematoxylin and eosin. $\times 4$. AFIP Neg. 65-1411.



6b

FIG. 6b. An acid-fast stain of a section, adjacent to the one above, demonstrates the concentration of mycobacterial colonies in the center of the necrotic zone. Ziehl-Neelsen stain. $\times 4$. AFIP Neg. 65-1413.



6c

FIG. 6c. A higher power of the same section shows the formation of mycobacterial colonies within dead fat cells. Ziehl-Neelsen stain. $\times 440$. AFIP Neg. No. 65-1412.

biopsy) contained viable cutaneous adipose tissue intermingled with lobules of necrotic fat, but none of these sections contained acid-fast bacilli. There were calcium de-

posits throughout but these were most striking in the region of the mycobacterial colonies. The drawing (Fig. 7) illustrates these observations.

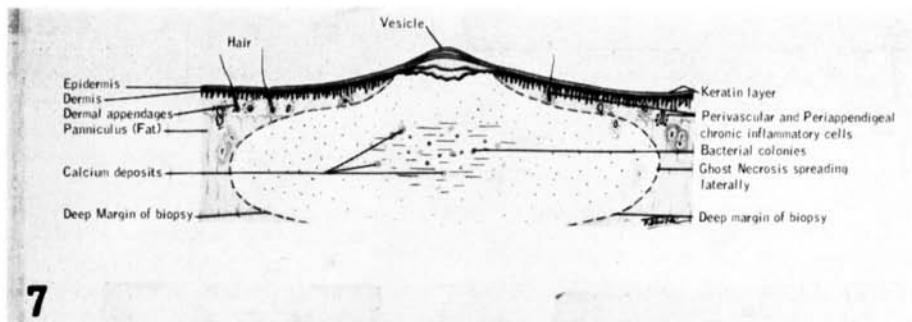


FIG. 7. This is a drawing, to scale, through the long axis of the lesion. The mycobacterial colonies are concentrated in the center of a broad zone of bland or noninflammatory necrosis. The latter has undermined the dermis and epidermis and is on the verge of erupting over the center of the lesion. *M. ulcerans* may produce a toxic substance which causes this necrosis.

DISCUSSION

Nothing is known of the natural reservoir or method of transmission of *M. ulcerans*, but the fact that patients live along rivers in Uganda⁽⁵⁾ and the Congo⁽³⁾ suggests that people are infected in or near the water. Although the present case does not help solve the epidemiologic problems, it sheds light on the mechanisms of the pathologic process. The necrotic cells are swollen and the intercellular spaces are expanded by homogeneous eosinophilic material, thus explaining the clinical swelling. The diffuse mineralization and the avascularity probably account for the induration. More importantly, the case described shows that proliferating colonies of *M. ulcerans* cause expanding noninflammatory necrosis in the panniculus, and it is clear also that this necrosis leads to ulceration by undermining viable corium. Especially significant is the fact that the acid-fast bacilli are concentrated in the center of the necrotic zone, remote from viable tissue. This feature suggests that *M. ulcerans* elaborates a diffusible toxic substance, and this idea gains plausibility when the extensive area of necrosis is contrasted with the smaller central zone in which the organisms are concentrated.

In relation to the possibility that *M. ulcerans* elaborates a diffusible necrotizing substance, our findings suggest that it acts in one of two ways. It could be proteolytic effect (its most striking result being the destruction of fat cell nuclei, leaving for a

few weeks the identity of cell boundaries and contents), or it could, in a more subtle way, interfere with cell metabolism, causing contiguous cells to swell, obliterating capillaries and resulting in ischemic necrosis. If *M. ulcerans* elaborates a necrotizing toxic substance, we can, with present facts, do no more than speculate about its mode of action.

The greatest bacterial proliferation takes place in the panniculus, but the reason for this is obscure. The panniculus may supply optimum nutrient or its temperature may be optimum for multiplication of the bacillus. The microscopic appearance (Fig. 6c) leaves no doubt that fat cells provide an adequate nutrient medium for exuberant proliferation, but *M. ulcerans* has such a fastidious temperature requirement (33°C) that its remarkable proliferation in the subcutaneous adipose layer may be a reflection of this characteristic. Rothman⁽⁶⁾ has shown that normal (internal) body temperature is maintained to within about 2.4 cm. of the skin surface. From here out the temperature steadily falls, approaching the ambient temperature on the skin surface (provided, of course, that the skin is not covered). The greatest rate of change in temperature (maximum thermal gradient), therefore, is within the subcutaneous fat and lower dermis, and thus, a temperature of 33°C at some level of the panniculus should occur. Fenner's observations and conclusions from experimental infections⁽²⁾ support the view that temperature is the critical factor in determining the site

of *in vivo* growth. By inoculating mice intravenously, he produced lesions of scrotum, tail, feet, nose, and ears, i.e., in the peripheral hairless (cool) parts. Also, when he inoculated chick embryos intravenously and incubated them at 33°C, bacilli increased in number in the liver, but when incubated at 37°C the organisms failed to grow and disappeared. These two lines of evidence support the view that skin temperature is the critical factor that promotes *M. ulcerans* growth in, and at the same time limits its growth to, the panniculus.

SUMMARY

Mycobacterial ulceration is a severe disease affecting a large number of people living along the Nile in Uganda. In a histopathologic study of 38 cases of *M. ulcerans* infection, we observed one case in the preulcerative state. The lesion consisted of a central nidus of mycobacterial colonies surrounded by a wide zone of necrotic tissue. The implications of these findings have been discussed and the suggestion made that *M. ulcerans* elaborates a diffusible toxin that causes tissue necrosis.

REFERENCES

1. CLANCEY, J. K., DODGE, O. G., LUNN, H. F. and ODUORI, M. L. Mycobacterial skin ulcers in Uganda. *Lancet* ii (1961) 951-954.
2. FENNER, F. The pathogenic behavior of *Mycobacterium ulcerans* and *Mycobacterium balnei* in the mouse and the developing chick embryo. *American Rev. Tuberc.* **73** (1956) 650-673.
3. JANSSENS, R. G., QUERTINMONT, M. J., SIENIAWSKI, J. and GATTI, F. Necrotic tropical ulcers and mycobacterial causative agents. *Trop. Geogr. Med.* **11** (1959) 293-312.
4. JELLIFFE, D. B., BURKITT, D., O'CONOR, G. T. and BEAVER, P. C. Subcutaneous phycomycosis in an East African child. *J. Pediat.* **59** (1961) 124-127.
5. LUNN, H. F., CONNOR, D. H., WILKS, N. E., BARNLEY, G. R., KAMUNVI, F., CLANCEY, J. K. and BEE, J. D. A. Buruli (mycobacterial) ulceration in Uganda. *E. African Med. J.* **42** (1965) 275-288.
6. LUNN, H. F. and REES, R. J. W. Treatment of mycobacterial skin ulcers in Uganda with a riminophenazine derivative (B-663). Preliminary communication. *Lancet* i (1964) 247-249.
7. MACCALLUM, P., TOLHURST, J. C., BUCKLE, G. and SISSONS, H. A. A new mycobacterial infection in man. *J. Path. Bact.* **60** (1948) 93-122.
8. ROTHMAN, S. *Physiology and Biochemistry of the Skin*. Chicago, University of Chicago Press, 1954, 251-253.

DISCUSSION

Dr. Binford. (in chair for Dr. Feldman, who was called away). In addition to being a pathologist skilled in tropical medicine Dr. Connor is an accomplished photographer. He made the clinical pictures he has shown this morning. One thing that had impressed me about this disease in Uganda was that in the trips that Dr. Connor with his associates made into the country where the ulcers were endemic, he found that in some areas, if the local hospital authorities had taken all cases needing admission, they would have filled all of their beds with patients suffering from mycobacterial ulcers. They could admit only those most severely affected.

In discussing this condition today, we are fortunate to have with us again Professor Janssens, whom you heard earlier this week in the discussion of leprosy research in a tropical disease institute. Professor Janssens was with us at the conference in Baltimore in 1961. At that time we spent a delightful evening hearing him present the experiences with this disease in the Congo. Before introducing him I would like to say that Dr. S. R. Pattyn, who also is from that Institute, and who was with us at our conference in Carville in 1958, after going back to the Congo, sent material to the Armed Forces Institute of Pathology from several patients with mycobacterial ulcers.

Prof. Janssens. First of all, I want to congratulate Dr. Connor for his excellent presentation on this disease, which I am very familiar with. He did a fine piece of work, and was especially lucky in being able to see many very early cases and study them carefully. I wish to thank him, too, because it was, for me, a real pleasure to go back, in another place, to a problem that has troubled me for quite a while. As everybody knows, it is always a pleasure and a special one in the field of mycobacteria, to find one's work confirmed by other colleagues.

For some time I had the queer privilege of standing by myself next to the Australian group with its six cases of this bizarre ulcerative condition of the skin—and to Van Oye and Ballion, who did describe a single case, which was studied later in the United States by Melleny and Johnson. At that time authors were more numerous than patients. I was the only one who had seen an important group of about one hundred patients. This happened because of the clinical sense of a friend of mine, Lubicz, who was surprised to find acid-fast bacilli in so-called tropical ulcerations resistant to classic treatment. Obviously those patients did not have leprosy. Out of more than 80 patients, I was unable to cultivate the organisms. Fortune did not favor me as it did the Australians, since my incubator stayed at 37°C all the time. At room temperature, I did not succeed, either. I was fortunate enough, however, to isolate in animals a good strain from a still closed lesion of the type you have just seen. This mycobacterium was going very well in the testes of white rats, the only suitable laboratory animal readily available under my field conditions in the Congo in the years 1942-1946. For once luck was on my side, for the rat happened to be the best animal for the purpose.

I did not publish my findings at that time, being not at all satisfied with my too fragmentary microbiologic study. I tried to get other people interested in the problem, but nobody believed in it. In 1950, when Van Oye published his case, the evidence he produced was, in my opinion, so slight that I decided to give my own facts

in a discussion of his paper. I did it in my own language, Flemish. Although I expected it to remain unnoticed, it was taken up in the United States.

Some years later I had to take care of the scientific aspects of our Institute's field hospital at Kasongo in the Maniema (Congo), located a good thousand miles or more to the south of the first *M. ulcerans* focus. Incidentally Kasongo is the place where Dutton made his last discovery, *Borrelia duttonii*, and where he is buried. Our hospital is rightly dedicated to this great personality. On this historic spot we tried to induce our doctors to look after necrotizing skin ulcers. They looked around for a while and, surprisingly enough, collected a few cases. They had never seen this ulceration before in their dispensaries or in the hospital. The reason for this is that the Congolese knew of this particular type of ulceration, but had learned from experience that European doctors were no better in that particular field than their native witch counterparts. So this new focus provided us with good material. When I visited the place again in 1963 there were still about ten new patients in the hospital. Later—and that is one of the points that is not shown in Dr. Connor's map—cases were found more to the south in the Katanga, and recently quite a few have been seen in Leopoldville and the Lower Congo. I am convinced that there may be cases all over Africa, at least in environmental conditions similar to those where Dr. Connor has been working, and where I found mine. The tropical rain forests might be the possible exception. I think that Dr. Browne could give an opinion on this point, because he is familiar with everything in the dermatologic field in the rain forests.

When I visited Upper Volta recently I tried to get my French colleagues interested in the problem, but without success. I wonder if, in Nigeria, where many surroundings are of about the same type as in the northeast of Congo and the northwest of Uganda, Dr. Browne has not come across some cases.

To make things short, we obtained the information we needed, except, perhaps, on the bacteriologic side. I would be glad,

Mr. Chairman, if my colleague, Dr. Pattyn might give briefly some information on that side of the problem. The overall bacteriologic picture has changed in the last few years, and in my opinion, besides *M. ulcerans*, many others of the so-called pseudo *M. leprae* are important for study. They have been found on many occasions ever since 1887, when Bordoni-Uffroduzzi isolated, for the first time, an acid-fast organism from leprotic tissues. Since then, as you know, with *M. marianum* and others, the list has extended indefinitely. I do not know if these organisms are occasionally pathogens, or are mere providers of some growth factors, but to my mind it would be important to get more microbiologic information on them. They might be able to shed some light on the pathogenesis of leprosy.

Dr. Binford. Thank you very much, Professor Janssens. Dr. Feldman, who was chairman of this session until called away by an emergency, was one of the first persons in the United States to work on *M. ulcerans*; he reported on it several years ago in the American literature. Dr. Pattyn, we would be very much pleased to hear now from you.

Dr. Pattyn. We have been able to study about a dozen strains isolated since about 1961 at Lovanium University in Leopoldville. An important fact is that investigators down there found that the cases could be divided into two main groups, one in which isolation was not at all difficult. The residue after decontamination of biopsy specimens contained numerous acid-fast bacilli. When put on Loewenstein-Jensen medium these grew in numerous colonies, at 30°, 33° and even 37°C. From the second group of cases, however, the bacteria were extremely difficult to grow. The same number of acid-fast bacilli put on Loewenstein-Jensen media permitted the isolation of only an occasional colony in one of the tubes at any of the temperatures used. However, once the bacilli grew, there was no difficulty whatever in keeping them on further passage. They grew rather slowly on transfer with loops, in about two to three weeks, like ordinary tubercle bacilli.

When the generation time is studied by inoculating very minute amounts and dilutions in tubes, however, it comes out quite clearly that these microorganisms do not grow at 37°C, but only at 33°, with a generation time between 24 and 48 hours. We have the impression, therefore, that in the evolution of the disease, there are periods in which the microorganisms are easily isolated and other periods when they die off and are difficult to obtain *in vitro*. This hypothesis was illustrated in a patient we saw at the Tropical Institute in Antwerp, who had been repatriated from the Congo. It was quite difficult to obtain cultures from the original lesion on the foot, but a few weeks later he developed metastatic lesions in other parts of the body, and from biopsy specimens from these lesions normal bacterial growth was easily obtained. So far as the bacteriologic character of the germs is concerned, we could not find any difference between them and several strains of *M. ulcerans* isolated in Australia, and we concluded that the Congolese strains were also *M. ulcerans*. I would like to close by saying that we tried to isolate *M. ulcerans* from soil in and around houses where patients had been seen, but without success.

Dr. Binford. Dr. Browne, can you answer Professor Janssens' question?

Dr. Browne. I was, of course, aware of the work of MacCallum in the mid 1940's and from then onward systematically examined every case of tropical ulcer that came to our hospital in the rain forest near Stanleyville. In the course of years we must have examined some three or four thousand ulcers from the point of view of *M. ulcerans*, especially after Van Oye and my friend, Professor Janssens published their work. But in no case could we discover the presence of anything resembling *M. ulcerans* ulceration in the tropical rain forest. There are two patients in Nigeria now under investigation for this condition. They come not from the tropical rain forest, but from the north, where there is a dry season 5 to 7 months of the year. There are also one or two other patients who might come into the category of slowly resolving

ulceration of this type, who are still under investigation. I would close by mentioning the clinical resemblances between incipient ulceration of this type and the plaques of subcutaneous mucormycosis known to occur not only in the Dutch East Indies but elsewhere.

Dr. Binford. Dr. Rees has had some experience with this organism in assisting Mr. Lunn in Uganda in treatment.

Dr. Rees. Our group, in conjunction with my colleague and friend, Mr. Fletcher Lunn, with whom Dr. Connor spent much time, became interested in this condition from the point of view of chemotherapy with the rimino-phenazine derivative B.663. Our studies on experimental infection in mice had results in a fairly satisfactory screening test for drugs, before we became interested in Mr. Lunn's mycobacteria. I shall show two slides as illustrations.

Figure 1 shows the foot pad of each of a pair of mice picked out at almost six weeks from a standard screening test with B.663. Both foot pads were inoculated with *M. ulcerans*. The animal on the right acted as an untreated control; the figure shows

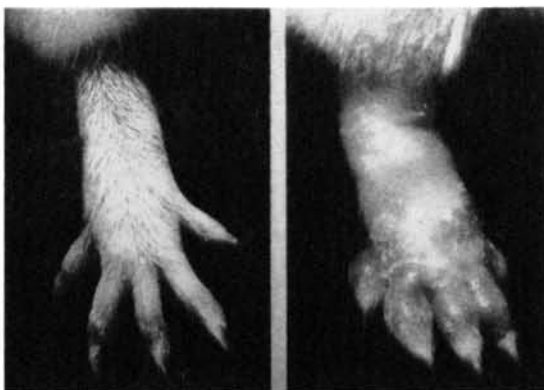

FIG. 1. *M. ulcerans* infection of mouse foot pad. Left, treated; right, untreated.

clearly that in the mouse foot pad inoculated with *M. ulcerans* you can replicate the type of result that Dr. Connor has described so well in man. The animal whose foot pad is shown on the left was given B.663 in its diet, and, in complete contrast to the untreated animal, there is no evidence of any macroscopic change, and the developing infection has been completely inhibited.

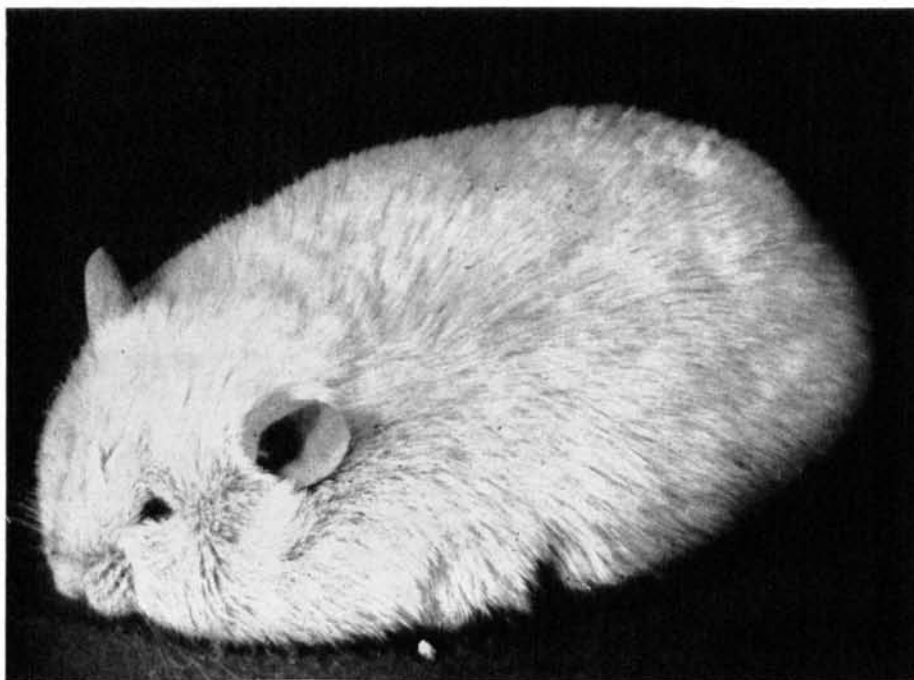

FIG. 2. Spreading general edema in mouse after foot pad inoculation.

B.663 is one of the very few antimycobacterial drugs that seem to have any degree of activity *in vitro* against *M. ulcerans* (M.I.D. 0.03 micrograms per ml.) and also, as you see, can inhibit a developing infection. As you may know from our early publications, this is the only drug that seems to have had any success in man for treating these lesions and reducing the amount of surgery that is normally carried out. Now, on the geographic pathology side, one thing will interest you. In our unit in Malaysia, in collaboration with Dr. J. H. S. Pettit, in the last 12 months we have picked up, in the rain forest, four cases that are now confirmed bacteriologically. The clinicians in Malaysia now recognize that they have seen this condition before, and there are undoubtedly many more cases. These four are responding extremely well to B.663.

Dr. Connor hazarded a guess that this mycobacterium, unlike other mycobacteria, may produce a toxin, possibly an enzyme. An interesting and characteristic fact observed in our animals after inoculation in the foot pad—and this was mentioned by

Jean Tollhurst in the original paper from Australia—is that a progressive spreading edema develops. Figure 2 shows a very nice example of it, viz., the results of a foot pad inoculum about 8-10 weeks after infection. There seems to be something very specific about *M. ulcerans* in giving rise to this condition.

Dr. Binford. Dr. Latapí would like to speak about a case in the New World.

Dr. Latapí. I would like to recall that in the American continent only one case has been discovered; that was in 1952 in the central part of Mexico. Acid-fast bacilli were found, and the organism was cultured at a lower temperature than normal. It was inoculated, and our findings were confirmed by Middlebrook and other investigators. The case was reported in the INTERNATIONAL JOURNAL OF LEPROSY (Aguilar, P.L., 21 (1953) 469-476). I believe more cases would be found if physicians knew more about the disease.

Dr. Binford. Thank you, Dr. Latapí. It is worthwhile bringing that experience into the records of this meeting.