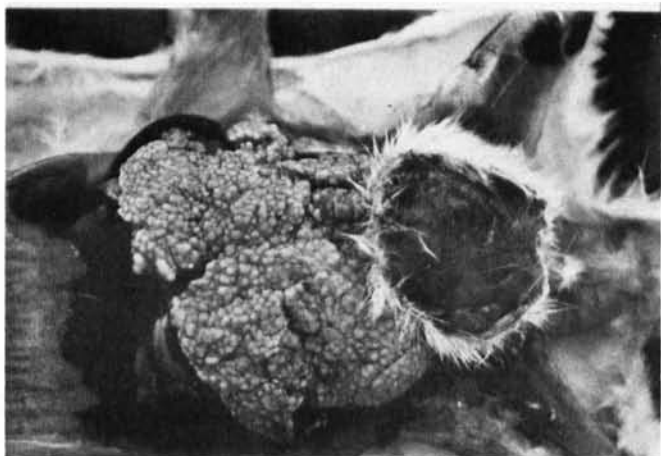



VII. Animal Heroes of the Century

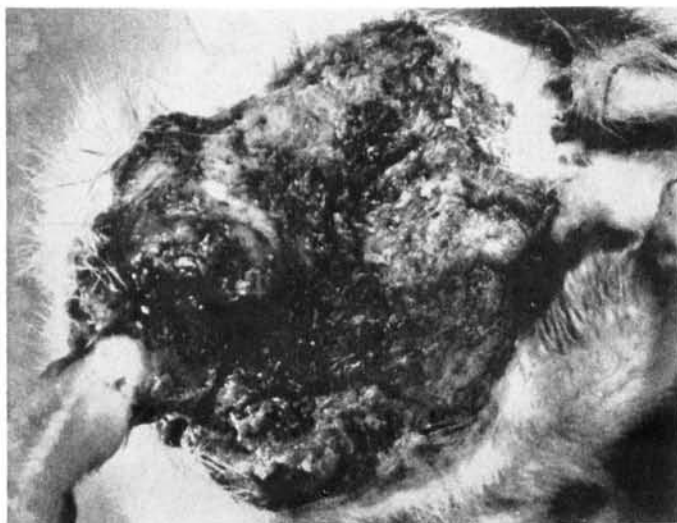
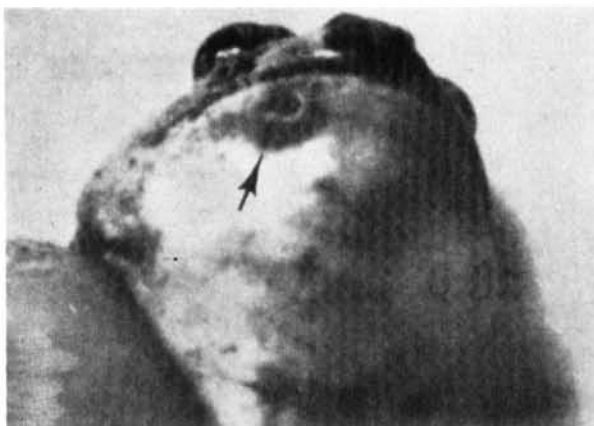Murine leprosy in rat. Stefansky, 1903.

Lepra bubalorum in water buffalo. Kok & Roseli, 1926; Lobel, 1934.



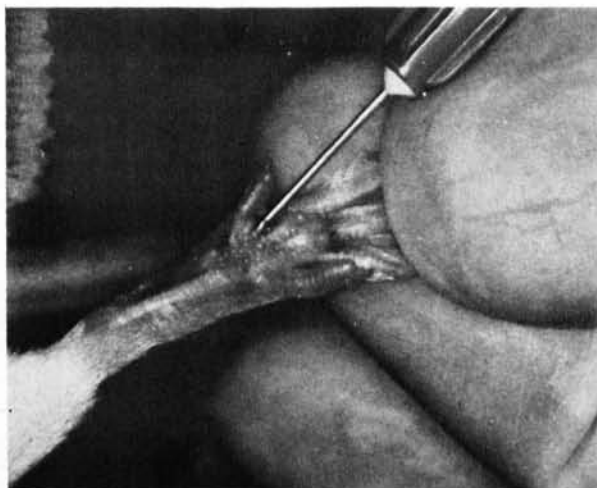
Limited M. leprae induced lesions (arrow) in monkey. Cochrane, 1947.

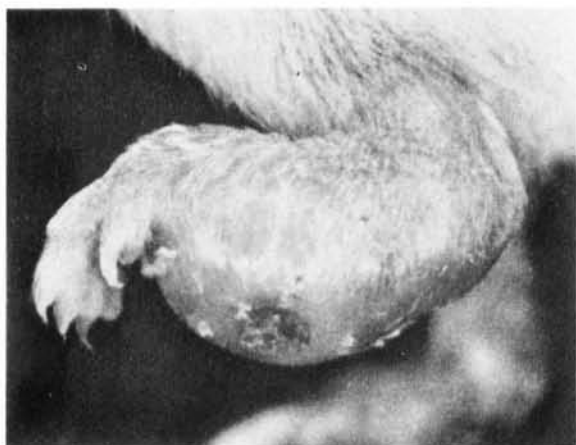Mycobacterial disease (arrow) in frog, having some resemblance to leprosy. Machicao & La Place, 1954.



M. leprae intramuscularly in irradiated rat. Carpenter & Naylor-Foote, 1959.



M. leprae in mouse foot pad. Shepard, 1960.





M. leprae dissemination in thymectomized, irradiated, bone marrow infused mouse. Rees, 1966.

M. leprae in irradiated, anti-lymphocyte serum treated Lewis rat. Fieldsteel & McIntosh, 1971.



M. leprae dissemination in thymectomized, irradiated with partial lead shielding, mouse. Binford & Walsh, 1971.

M. leprae, disseminated infection in armadillo. Kircheimer & Storrs, 1971.

