

# Involvement of the Gastrointestinal Tract in Leprosy<sup>1</sup>

S. Kaur, S. K. Mehta, B. Kumar, R. N. Chakravarty  
and H. K. Sidhu<sup>2</sup>

Recent clinical and experimental studies provide ample evidence that leprosy is a systemic disease. With the exception of tissues such as the central nervous system, lungs and perhaps kidneys, all of the other organs are involved. The published literature relating to leprosy involvement of the gastrointestinal tract is scanty and conflicting (2, 5, 10, 17, 21). Experimentally leprosy has produced extensive involvement of the gastrointestinal tract in the armadillo (11); though rats and mice escape such an involvement.

The emphasis in the previous studies has been on the histopathologic changes alone and the functional status of the gastrointestinal tract has not been studied.

## MATERIALS AND METHODS

Twenty-five patients suffering from leprosy were selected at random for study from the Dermatology Outpatient Department of the Postgraduate Institute of Medical Education and Research Hospital, Chandigarh, India. Clinical examination included a detailed history of dietary intake and symptomatology pertaining to the gastrointestinal tract. Fifteen patients were classified as lepromatous, five as dimorphous (borderline), and five were of the tuberculoid variety (Indian classifications are used) (32). The ages of the patients ranged from 16-70 years and the duration of their illness varied from one month to fifteen years.

Investigations included examination of urine and repeated stool examination for intestinal parasites, estimation of blood urea, serum creatinine, liver function tests

including total and differential serum proteins, alkaline phosphatase and serum bilirubin. Skiagrams of the chests were made to rule out pulmonary tuberculosis. The gastrointestinal functions were evaluated in detail. Gastric secretion was determined by the augmented histamine tests using the modified method of Baron (1). The dose of histamine used was 0.06 mg/kg body weight. The indirect immunofluorescence technic using fresh rat stomach was used to determine circulating parietal cell antibody (18). Peroral gastric biopsy was obtained using Crosby's capsule. Small bowel absorption functions and morphology were assessed by a 72 hour stool fat estimation (31) after the individual had been on a 75 gm fat diet for six days. Five hour urinary d-xylose excretion was estimated after an oral dose of 25 gm (22) and B<sub>12</sub> absorption was studied by the Schilling method (26) after feeding 1 µc/µg of 58 Co B<sub>12</sub> orally. Peroral jejunal biopsy was obtained by Crosby's capsule. Sections of gastric and jejunal biopsies were stained with hematoxylin and eosin, Ziehl-Neelsen for *M. leprae* and metachromatic stains for amyloid. The jejunal biopsies were graded appropriately (27). Barium meal skiagraphy was performed with a nonflocculating medium (Cremobar) and interpreted using the method of Paterson *et al* (20). This helped in excluding secondary causes of malabsorption. The barium meal was followed up to the ileocecal region.

## RESULTS

No patient in this series had gastrointestinal symptoms and none suffered from active tuberculosis. The socioeconomic status of this group of patients was moderately good. All were gainfully employed. Their daily calorie intake was approximately 1,700 calories. The diet was fairly adequate in vitamins, the 24-hour protein consumption was around 50 gm. There were no skin, hair or serum protein changes to suggest malab-

<sup>1</sup> Received for publication 14 June 1977.

<sup>2</sup> S. Kaur, M.D., M.A.M.S., Assistant Professor of Dermatology; S. K. Mehta, M.D., M.A.M.S., Associate Professor of Gastroenterology; B. Kumar, M.D., Lecturer in Dermatology; R. N. Chakravarty, M.B.B.S., D. Phil., M.A.M.S., F.I.C.A., D.I.M., Associate Professor of Experimental Medicine; and H. K. Sidhu, M.S., Resident Doctor, Department of Medicine, Postgraduate Institute of Medical Education and Research, Chandigarh, India.

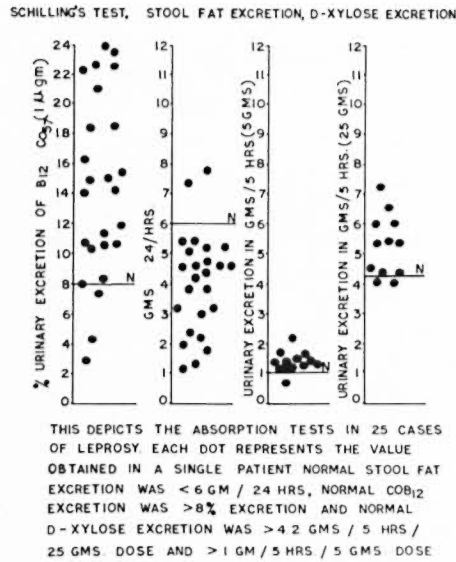


FIG. 1. Absorption tests in 25 cases of leprosy.

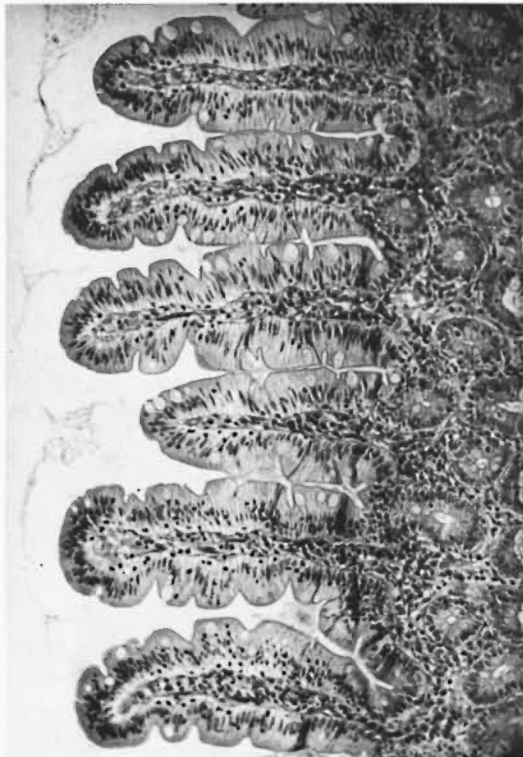

FIG. 2. Light microscopic appearance of jejunal mucosa showing normal finger-like villi. Epithelial cells are columnar and cellular infiltrate is of a mild degree. The villous crypt ratio is normal. (H & E stain,  $\times 100$ )

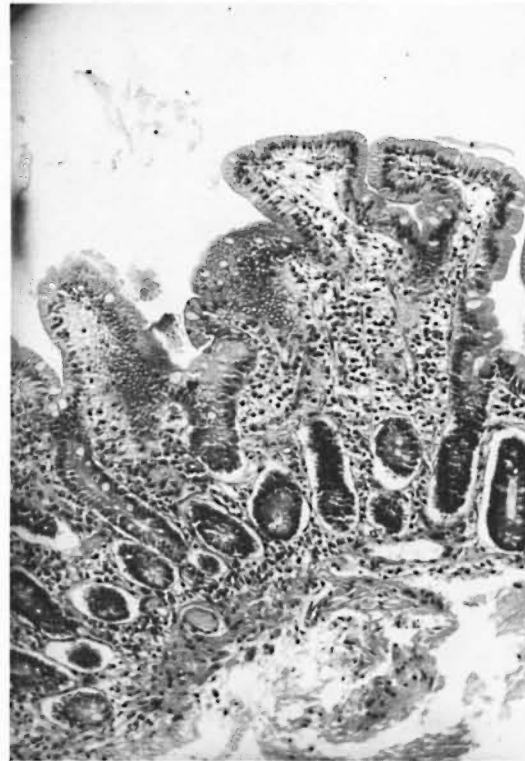


FIG. 3. Light microscopic appearance of jejunal mucosa showing short and broad villi with fusion and increased cellular infiltrate in the corium. The crypts are elongated and the villous crypt ratio is altered. Grade II PVA. (H & E stain,  $\times 100$ )

sorption. Only one patient had mild anemia. The mean hemoglobin in the group was  $13.11 \text{ gm}\% \pm 1.80$ . The packed cell volume ranged from 28% to 52% with a mean of  $41.36\% \pm 5.84$ . The mean total protein level was  $6.58 \text{ gm} \pm 0.75$  and the mean serum albumin was  $3.16 \text{ gm} \pm 0.48$ . It was lowered in 11 patients, the lowest figure being 2.2 gm%. The mean serum globulin level was  $3.46 \text{ gm} \pm 0.86$ . The globulins were raised in eight patients, the maximum value being 5.2 gm%.

Mild steatorrhea (7.1 and 7.8 gm/24 hrs) was present in two patients (the normal value for our laboratory is < 6 gm/24 hrs). The d-xylose excretion determination after a 5 gm dose was abnormal in one of thirteen patients (the normal excretion is > 1 gm/5 hrs). It was abnormal in two of twelve patients when performed with a 25 gm dose (normal excretion being > 4.0 gm/24 hrs). The Schilling test was abnormal in three of twenty-five patients (normal value being > 8% excretion) (Fig. 1). Barium meal study

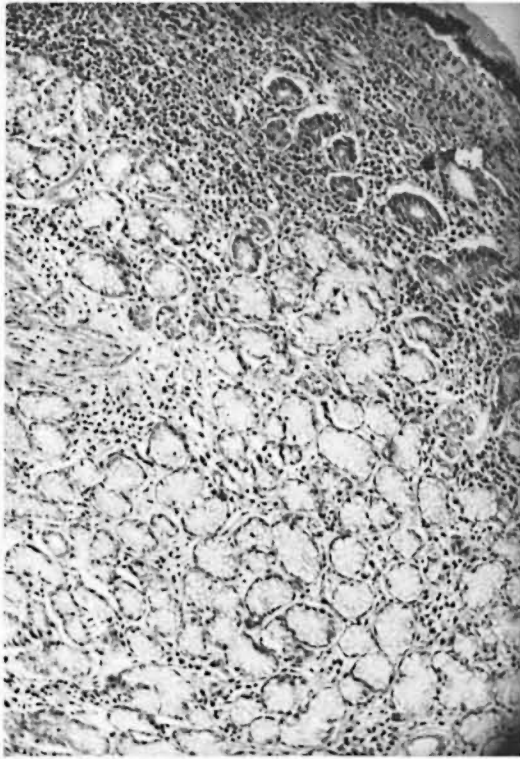


FIG. 4. Light microscopic appearance of stomach mucosa obtained from the body of the stomach, showing a moderate degree of gastritis. There is a marked increase in the inflammatory cellular infiltrate in the superficial mucosa and between the glands. (H & E stain,  $\times 100$ )

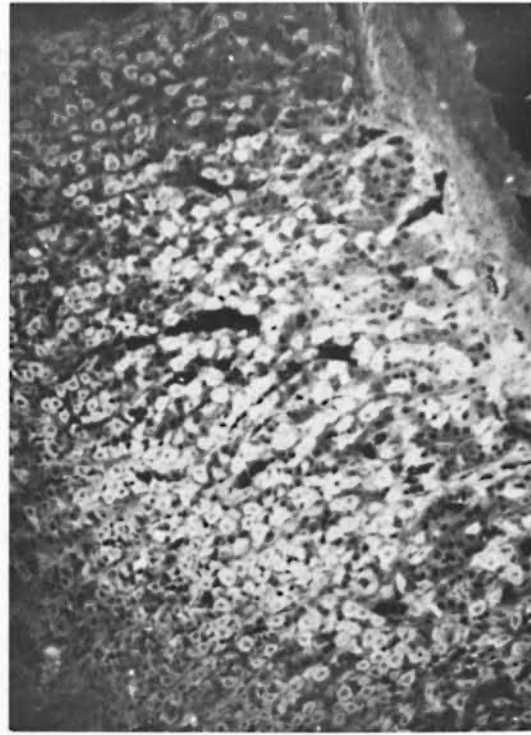


FIG. 5. Indirect immunofluorescence study using fresh rat stomach showing circulating parietal cell antibody in one of the patients.

and transit time were normal in all of the patients. Jejunal biopsies were successful in 20 of 25 patients. In eight the biopsy was interpreted as normal (Fig. 2). Five of these patients had normal intestinal absorption but three showed abnormal Schilling tests. In the remaining 12 patients the biopsy was abnormal. Grade I partial villous atrophy (PVA) was detected in five cases, four of these having normal biochemical parameters. The fifth case had mild steatorrhea and abnormal d-xylose excretion. Seven patients had grade II PVA (Fig. 3). Malabsorption was found in only two of these patients. One had abnormal excretion of d-xylose and the other had a mild d-xylose and B<sub>12</sub> malabsorption. None of the jejunal biopsy sections showed leprous granulomata, *M. leprae* or amyloid deposit.

The augmented histamine test was within normal limits in all patients. The mean BAO (basal acid output) was  $1.30 \text{ mEq/L} \pm 0.99$

(normal being 1-5 mEq/L), and MAO (maximum acid output) was  $8.92 \text{ mEq/L} \pm 5.14$  (normal being 5-30 mEq/L). Gastric biopsy was available in 21 patients. Changes indicative of gastritis were noted in ten of these; mild in eight and moderate in two cases (Fig. 4). Circulating parietal cell antibody (PCA) was detected in three of thirteen patients in whom it was investigated (Fig 5). There was no correlation between gastric histology and parietal cell antibody titer. Gastric histology was normal in two of the three patients in which parietal cell antibody was present and showed mild gastritis in the third patient. In the remaining ten patients where the parietal cell antibody was absent the gastric histology revealed mild gastritis in three and moderate changes in one. Leprous lesions, leprosy bacilli and amyloidosis were not present in any of the gastric biopsy sections.

#### DISCUSSION

Leprosy is now regarded as a systemic disease (<sup>4,14</sup>). A continuous bacilleemia pres-

ent in patients having untreated lepromatous disease is responsible for the multi-organ involvement (7, 24, 29). The visceral involvement in lepromatous leprosy is extensive, mainly affecting the organs rich in reticuloendothelial elements such as the liver, spleen, bone marrow and lymph nodes (2, 5, 6). The only organs which escape leprous involvement are the brain, spinal cord, lower respiratory passages, lung parenchyma, kidney and urinary tract. The existing literature regarding the specific involvement of the gastrointestinal tract in leprosy is controversial. Bernard and Vazquez (2) found bacilliferous infiltrates interspersed between the gut musculature in autopsies on patients having lepromatous leprosy. In an earlier study (5), no such involvement was reported. The latter also did not find involvement of mesenteric and mediastinal lymph nodes. The hepatic portal and pelvic lymph nodes, on the other hand, were shown to have extensive foam cell aggregation. Specific involvement of muscle layers of the small intestine could not be confirmed in the present study; the biopsy material, having been obtained with a Crosby capsule, could not include the muscular layer.

A few antemortem studies are available on the involvement of the stomach in leprosy (13, 15). Koshy *et al* (13) observed leprosy bacilli in the gastric juice of nine of the sixteen patients studied and three of them also excreted bacilli in the feces. They attributed these bacilli to contamination from the nose and nasopharynx or upper respiratory tract. No leprosy bacilli were detected in 50 gastric biopsies on patients having lepromatous leprosy (13).

Manzullo *et al* (15) detected acid-fast bacilli in seven of twenty samples of biliary secretions and in two of seven samples of feces. *M. leprae* were not found in any gastric biopsy in the present study. The acid secreting function was also found to be normal as judged by the augmented histamine test. It has been found that 7% to 10% of the local healthy population have parietal cell antibody, thus the abnormality found in three of our patients may be quite unrelated to the leprous infection. This was supported by minimal gastric histopathologic changes and no disturbance in the parietal cells.

The cause of mild gastritis in two patients could be attributed to drugs, smoking or ir-

ritant foods. In the autopsy studies on lepromatous patients, involvement of the small intestine has been described in the form of bacilliferous and histiocytic infiltration and amyloid deposits (17, 21, 28). No such involvement was found in the jejunal biopsies studied by us nor was there any evidence of acid-fast bacilli or amyloidosis.

Intestinal absorption studies revealed mild steatorrhea in two patients (8%), one each belonging to the lepromatous and tuberculoid variety, the steatorrhea being asymptomatic clinically. D-xylose malabsorption was observed in three patients (12%), mild malabsorption of B<sub>12</sub> and fat was also present in these cases. The indigenous population of the tropics has sizeable disturbances of various small bowel absorption tests, leading to tropical enteropathy. The mild absorption derangement, supported by normal barium meal studies seen in a small number of patients may, therefore, be unrelated to leprosy.

The jejunal mucosal pattern did not entirely correlate with the biochemical malabsorption, only two of the seven patients having Grade III partial villous atrophy on histology had biochemical evidence of malabsorption. The absence of correlation between jejunal histology and tests for malabsorption is well documented (12). The jejunal histology studies from India and other tropical countries are reported to show mild degrees of change even in apparently normal people, unlike persons living in the Western hemisphere where one finds tall finger-like villi in all normal persons (25, 30). Situated in a region where a large segment of the normal healthy population has some disturbances of absorption and morphologic changes in the jejunal mucosa, the presence of mild mucosal abnormalities in seven patients could not be attributed to leprosy, particularly when the lamina propria did not contain large numbers of macrophages, leprous granulomas, amyloid deposits or *M. leprae*. The disturbances in serum proteins also do not seem to be related to the malabsorption process. The serum protein abnormalities seen in 18 of 25 patients, including hyperglobulinemia in 8 patients, can be ascribed to a response of the reticuloendothelial system (23).

The only other reported antemortem study where the functional status of the small in-



testine was studied in leprosy is that by Noronha (19). He found a high incidence of malabsorption of fat (12%), d-xylose (76%), and B<sub>12</sub> (68%) in 50 patients. Barium study confirmed the malabsorption in 34% of the patients. Surprisingly, partial villous atrophy was found in only three patients (6%). The malabsorption was attributed to a direct or indirect involvement of the small bowel by the leprosy process. The disparity between our findings and those of Noronha is not easy to explain. There do seem to be differences in the nutritional status of the two population groups studied. Our patients belonged to a moderately good socio-economic status, were all employed, consumed a balanced diet and had no evidence of malnutrition or anemia. The patients studied by Noronha (19) were mostly unemployed, living on charity, consuming a diet inadequate in calories, and many had evidence of malabsorption which by itself can be responsible for intestinal malabsorption (3, 8, 9, 16). A cause and effect relationship of malabsorption to leprosy in these patients, as ascribed by Noronha is debatable. Further studies of intestinal absorption in patients of comparable socio-economic status suffering from leprosy are necessary to confirm our observations.

### SUMMARY

The published information about involvement of the gastrointestinal tract in leprosy is scanty and conflicting. Twenty-five patients having leprosy (L-15, B-5, T-5) were subjected to investigations pertaining to the gastrointestinal tract. None of the patients had symptoms of gastrointestinal disease, pulmonary tuberculosis or renal dysfunction. Anemia was mild in six (Hb < 10 gm%) and moderate in one patient (Hb < 9.0 gm%). Hypoalbuminemia (< 3.2 gm%) was present in eleven and hyperglobulinemia (> 3.5 gm%) in eight patients. Augmented histamine test was normal in all. Mild gastritis on histology was present in two patients; one was of the tuberculoid type and the other of the lepromatous variety. Leprous granulomata, *M. leprae* and amyloid were not detected in any section. Circulating parietal cell antibody (PCA) was detected in three of the thirteen patients studied. The corresponding gastric histology showed mild gastritis in only one. Of the ten patients with normal PCA, the gastric histology showed

various degrees of gastritis in four. Fecal fat malabsorption of a mild degree (7.1 and 7.8 gm/24 hrs) was found in two patients (8%), belonging to the lepromatous and tuberculoid variety respectively. D-xylose excretion was slightly deranged in three patients (12%), two were of lepromatous and one of tuberculoid variety. The Schilling test was abnormal in three patients (12%), one each belonging to lepromatous, tuberculoid and dimorphous varieties. Grade II partial villous atrophy (PVA) was observed in seven patients. Two of them had mild abnormality of absorption tests, one each belonging to lepromatous and tuberculoid variety. Granulomata, leprosy bacilli and amyloid were absent. Barium meal skiagrams were normal in all patients. Attempting to correlate the malabsorption tests and jejunal histology, abnormalities in two tests were present in two patients, one each belonging to lepromatous and tuberculoid varieties. The jejunal histology was Grade I PVA in the former and Grade II PVA in the latter. Four patients had a single malabsorption abnormality. Of these, two were of the lepromatous type, the jejunal histology being normal in one and Grade II PVA in the other. The other two were of the dimorphous type and both had normal mucosa.

Correlation was not found between type of leprosy, malabsorption and jejunal histology. A sizeable population in the tropics, even normally, has disturbances of absorption tests and jejunal mucosa. The percentages of abnormalities detected in the stomach and small intestine were not significant. It can thus be concluded that the gastrointestinal tract remains unaffected in leprosy.

### RESUMEN

La información publicada acerca de la afección del tracto gastrointestinal por la lepra es escasa y conflictiva. En este trabajo se estudiaron 25 pacientes con lepra (15-L, 5-B y 5-T) para investigar la presencia de lesiones en el tracto gastrointestinal. Ninguno de los pacientes estudiados tenían síntomas de enfermedad gastrointestinal, de tuberculosis pulmonar o de disfunción renal. Seis pacientes tenían anemia ligera (Hb < 10 g/100), uno anemia moderada (Hb < 9 g/100), once pacientes tenían hipoalbuminemia (< 3.2 g/100) y ocho tenían hiperglobulinemia (> 3.5 g/100). La prueba de la histamina aumentada fue normal en todos los pacientes. Desde el punto de vista histológico, hubo gastritis moderada en dos pacientes.

uno tuberculoide y el otro lepromatoso. En ningún corte se observaron granulomas leproso, *M. leprae* ó depósitos de amiloide. En 3 de 13 pacientes estudiados se encontraron anticuerpos contra las células parietales (ACP). La histología gástrica correspondiente mostró gastritis moderada sólo en uno de ellos. De los 10 pacientes sin ACP, el estudio histológico mostró varios grados de gastritis en 4 de ellos. En 2 pacientes (o el 8%), uno lepromatoso y el otro tuberculoide, se observó malabsorción de grasa fecal de grado moderado (7.1 y 7.8 g/24 hs). En 3 pacientes (12%), la excreción de D-xilosa estuvo ligeramente disminuída. Un paciente fue tuberculoide y 2 lepromatosos. La prueba de Schilling fue anormal en 3 pacientes (12%), uno lepromatoso, uno tuberculoide y uno dimorfo. En 7 pacientes se observó una atrofia vellosa parcial (AVP) del grado II. Dos de ellos tuvieron anomalía moderada en sus pruebas de absorción, de éstos, uno fue lepromatoso y el otro tuberculoide. En ningún caso se observaron granulomas, bacilos de la lepra ni amiloide. En todos los pacientes, las radiografías por contraste con bario parecieron normales. Correlacionando las pruebas de malabsorción con la histología yeyunal, se encontraron anomalías en dos pruebas en 2 pacientes, uno lepromatoso y el otro tuberculoide. En el primer paciente hubo una AVP del grado I y en el segundo una AVP del grado II. Cuatro pacientes tuvieron una sola anomalía en las pruebas de malabsorción. De éstos, 2 fueron lepromatosos (uno de ellos con histología yeyunal normal y el otro con una AVP del grado II) y 2 dimorfos (ambos con una mucosa normal). No se encontró correlación entre el tipo de lepra, malabsorción e histología yeyunal. En los trópicos, una importante parte de la población, incluyendo a las personas no leprosas, tienen alteraciones en sus pruebas de absorción y en la histología yeyunal. Los porcentajes de las alteraciones observadas en el estómago y en el intestino delgado no fueron significativos. Se puede concluir que en la lepra el tracto gastrointestinal permanece sin afectarse.

### RÉSUMÉ

Les informations qui ont été publiées concernant l'atteinte du système gastro-intestinal dans la lèpre sont rares et contradictoires. Chez 25 malades de la lèpre (15 lépromateux, 5 borderlines, 5 tuberculoïdes), on a procédé à des études de système gastro-intestinal. Aucun de ces malades ne présentait de symptômes de maladie gastro-intestinale, de tuberculose pulmonaire ou de malfonctionnement rénal. Une légère anémie a été notée chez 6 d'entre eux (Hb < 10 gm%), et une anémie modérée chez un malade seulement (Hb < 9,0 gm%). Chez 11 malades, on a noté une hypoalbuminémie (< 3,2 gm%), et de l'hyperglobulinémie (> 3,5 gm%) chez 8 mala-

des. L'épreuve à l'histamine était normale chez tous les malades. A l'examen histologique, on a noté une gastrite légère chez 2 malades; était atteint du type tuberculoide, et l'autre de la forme lépromateuse. Des granulomes lépreux, *M. leprae*, ainsi que de la substance amyloïde, n'ont été détectés dans aucune coupe. Des anticorps cellulaires pariétaux circulants (PCA) ont été détectés chez 3 des 13 malades étudiés. L'histologie gastrique correspondante révélait une gastrite légère chez seulement l'un d'entre eux. Parmi les 10 malades présentant une PCA normale, l'histologie gastrique a montré divers degrés de gastrite chez 4 d'entre eux. Une malabsorption des graisses dans les matières fécales a été observée à un degré léger (7,1 et 7,8 gm/24 heures) chez 2 malades (8%), l'un appartenant au type lépromateux et l'autre au type tuberculoide de la maladie. L'excrétion du D-xylose était légèrement perturbée chez 3 malades (12%), deux du type lépromateux et un du type tuberculoide. Le test de Schilling était anormal chez 3 malades, un lépromateux, un tuberculoide, et un dimorphe. Une atrophie partielle des villosités de degré I (PVA) a été observée chez 7 malades. Deux d'entre eux présentaient une anomalie légère des tests d'absorption, l'un étant lépromateux et l'autre tuberculoide. Des granulomes, des bacilles de la lèpre, et de la substance amyloïde, n'ont été notés dans aucuns de ces cas. Le skiagram alimentaire du barium était normal chez tous les malades. On a essayé de mettre en corrélation les épreuves de malabsorption et l'histologie du jejunum. Des anomalies des deux épreuves étaient présentes chez deux malades, un lépromateux et un tuberculoide. L'histologie jéjunale était du degré I PVA chez le premier, et du degré II PVA chez le second.

Quatre malades présentaient des anomalies simples de l'absorption. Parmi ceux-ci, deux étaient du type lépromateux, l'histologie jéjunale étant normale chez un, une PVA degré II ayant été observée chez le deuxième. Les deux autres malades étaient du type dimorphe, et tous deux présentaient une muqueuse normale.

On n'a pas observé de corrélation entre le type de lèpre, la malabsorption, et l'histologie du jejunum. Une partie notable de la population sous les tropiques, même en condition normale, présente des troubles des épreuves d'absorption et de la muqueuse jéjunale. Les pourcentages d'anomalies détectées au niveau de l'estomac et du petit intestin n'étaient pas significatifs. On peut en conclure que le système gastro-intestinal n'est pas affecté dans la lèpre.

### REFERENCES

1. BARON, J. H. Studies of basal and peak acid output with an augmented histamine test. *Gut* 4 (1963) 136-144.
2. BERNARD, J. C. and VAZQUEZ, C. A. J. Vis-

- ceral lesions in lepromatous leprosy. Study of sixty necropsies. *Int. J. Lepr.* **41** (1973) 94-101.
3. BRUNSER, O., REID, A., MONCKEBERG, F., MACCIONI, A. and CONTRERO, I. Jejunal mucosa in infant malnutrition. *Am. J. Clin. Nutr.* **21** (1968) 976-983.
  4. COCHRANE, R. G. Signs and symptoms. *In: Leprosy in Theory and Practice*, 2nd edit., R. G. Cochrane and T. F. Davey, eds., Bristol: John Wright and Sons, Ltd., 1964, p 135.
  5. DESIKAN, K. V. and JOB, C. K. A review of postmortem findings in 37 cases of leprosy. *Int. J. Lepr.* **36** (1968) 32-44.
  6. DESIKAN, K. V. and JOB, C. K. Visceral lesions caused by *M. leprae*, a histopathological study. *Indian J. Pathol. Bacteriol.* **13** (1970) 101-104.
  7. DRUTZ, D. J., CHEN, T. S. N. and LU, WEN-HSIANG. The continuous bacteremia of lepromatous leprosy. *N. Engl. J. Med.* **287** (1972) 159-164.
  8. GORBACH, S. L., BANWELL, J. G., JACOBS, B., CHATTERJEE, B. D., MITRA, R., SEN, N. N. and GUHA MAZUMDAR, D. N. Tropical sprue and malnutrition in West Bengal. I. Intestinal microflora and absorption. *Am. J. Clin. Nutr.* **23** (1970) 1545-1558.
  9. GUPTA, S. P., MEHTA, S. and WALIA, B. N. S. Small bowel functions in protein calorie malnutrition. *Indian Pediatr.* **7** (1970) 481-488.
  10. KEAN, B. H. and CHILDRESS, M. E. A summary of 103 autopsies on leprosy patients on the Isthmus of Panama. *Int. J. Lepr.* **10** (1942) 51-59.
  11. KIRCHHEIMER, W. F., STORRS, E. E. and BINFORD, C. H. Attempts to establish the armadillo (*Dasypus novemcinctus* Linn.) as a model for the study of leprosy. II. Histopathologic and bacteriologic postmortem findings in lepromatoid leprosy in armadillo. *Int. J. Lepr.* **40** (1972) 229-242.
  12. KLIPSTEIN, F. A., SAMLOFF, I. M., SMARTH, G. and SCHENK, E. Malabsorption and malnutrition in rural Haiti. *Am. J. Clin. Nutr.* **21** (1968) 1042-1052.
  13. KOSHY, A. and KARAT, A. B. A. A study of acid-fast bacilli in the urine, gastric juice and feces of patients with lepromatous leprosy. *Lepr. India* **43** (1971) 3-7.
  14. LOWE, J. Rat leprosy. A critical review of the literature. *Int. J. Lepr.* **5** (1937) 311-328.
  15. MANZULLO, A., MANZI, R. O., LEFEVRE, A. and OTEIZA, M. L. Investigation of AFB in the digestive tract of leprosy patients. *Leprolologia* **10** (1965) 14-16. Abstract in *Int. J. Lepr.* **35** (1967) 101.
  16. MAYORAL, L. G., TRIPATHY, K., GARCIA, F. T. and GHITIS, J. Protein malnutrition-induced malabsorption versus tropical sprue. *Gastroenterology* **53** (1967) 507-508.
  17. MITSUDA, K. and OGAWA, M. A. A study of 150 autopsies of cases of leprosy. *Int. J. Lepr.* **5** (1937) 53-60.
  18. NAIRN, R. C. *Fluorescent Protein Tracing*, 2nd edit., Edinburgh: E. Q. S. Livingstone, 1964, p 214.
  19. NORONHA, A. B. S. A study of the small intestine in cases of Hansen's disease with special reference to the relationship between nutritional deficiency and malabsorption. M.D. Thesis, Punjab University, 1971 (unpublished).
  20. PATERSON, D. E., DAVID, R. and BAKER, S. J. Radiodiagnostic problems in malabsorption. *Br. J. Radiol.* **38** (1965) 181-191.
  21. POWELL, C. S. and SWANN, L. L. Pathological changes observed in 50 consecutive necropsies. *Am. J. Pathol.* **31** (1965) 1131-1147.
  22. ROE, J. H. and RICE, E. W. A photometric method for the determination of free pentoses in animal tissue. *J. Biol. Chem.* **173** (1948) 507-512.
  23. ROSS, H. Clinical, biochemical and immunological studies in leprosy. *Lepr. India* **36** (1964) 93-107.
  24. SAXENA, H., AJWANI, K. D., PRADHAN, S., CHANDRA, J. and AJAI, K. A preliminary study on bacteremia in leprosy. *Lepr. India* **47** (1975) 79-83.
  25. SCHENK, E. A., SAMLOFF, I. M. and KLIPSTEIN, F. A. Morphology of small bowel biopsies. *Am. J. Clin. Nutr.* **21** (1968) 944-961.
  26. SCHILLING, R. F. The effect of gastric juice on the urinary excretion of radioactivity after the oral administration of B<sub>12</sub>. *J. Lab. Clin. Med.* **42** (1953) 860-866.
  27. SHEEHY, T. W., BAGGS, B., PEREZ-SANTIAGO, E. and FLOCH, M. H. Prognosis of tropical sprue; a study of the effect of folic acid on the intestinal aspects of acute and chronic sprue. *Ann. Intern. Med.* **57** (1962) 892-908.
  28. SHUTTLEWORTH, J. S. and ROSS, H. Secondary amyloidosis in leprosy. *Ann. Intern. Med.* **45** (1956) 23-38.
  29. SKINSNES, O. K. Significance of visceral lesions. *Int. J. Lepr.* **41** (1973) 456-461; Chairman, Committee 4, Xth Int. Lepr. Congress, 1973, Bergen, Norway.
  30. SPRINZ, H., SRIBHIBHADH, R., GANGAROSA, E. J., BENYAJATI, C., KUNDEL, D. and HALSTEAD, S. Biopsy of small bowel of Thai people with special reference to recovery from Asiatic cholera and to intestinal malabsorption syndrome. *Am. J. Clin. Pathol.* **38** (1962) 43-51.
  31. VAN DE KAMER, J. H., TEN BOKKEL HUININK, H. and WEYERS, H. A. Rapid method for determination of fat in feces. *J. Biol. Chem.* **177** (1949) 347-355.
  32. Indian Association of Leprologists Biennial Session, Jamshedpur, 1955; and Dharmendra in *Leprosy in India*, volume 32, 1960, p 7.