



# INTERNATIONAL JOURNAL OF LEPROSY

And Other Mycobacterial Diseases

VOLUME 49, NUMBER 1

MARCH 1981

## Histology of the Fernandez Reaction. An Appraisal<sup>1</sup>

J. Thomas, M. Joseph, K. Ramanujam, C. J. G. Chacko,  
and C. K. Job<sup>2</sup>

The early lepromin reaction or the Fernandez reaction was described in 1940 by the South American leprologist, Fernandez<sup>(3)</sup>, as an "erythematous infiltrated halo" around the point of inoculation of lepromin antigen, which appeared at 24 hr and reached a maximum between 48 and 72 hr. A well-developed early reaction is elicited by the Dharmendra antigen, which is a "defatted" suspension of leprosy bacilli, introduced by Dharmendra in 1942<sup>(2)</sup>.

The histology of the early reaction has thus far been studied only in the tuberculoid and lepromatous groups of patients<sup>(3,8,9)</sup>. This study attempts to characterize the histopathology of the reaction in the

entire spectrum of leprosy and evaluate its significance in leprosy patients.

### MATERIALS AND METHODS

Thirty-eight patients were selected for this study from the Schieffelin Leprosy Research and Training Centre, Karigiri, North Arcot District. They were classified on the basis of clinical, bacteriological, and histopathological criteria into five groups according to the method of Ridley and Jopling<sup>(7)</sup>: lepromatous (resolved), nine patients; borderline lepromatous, four; borderline tuberculoid, 12; tuberculoid, four; and indeterminate, nine. All of the patients belonging to the lepromatous group were bacteriologically negative.

The lepromin test was performed using the Mitsuda-Hayashi antigen, as modified by Wade<sup>(6)</sup>. The suspension was standardized to give a bacillary concentration of  $1.6 \times 10^8$  bacilli/ml; 0.1 ml of this antigen was injected intradermally on the flexor surface of the forearm in an area free of leprosy infiltration or other skin lesions. The location of the test site with respect to anatomical landmarks was recorded.

The clinical reaction was read at the end of 48 hr using a pair of vernier calipers.

<sup>1</sup> Received for publication on 8 July 1980; accepted for publication on 4 September 1980.

<sup>2</sup> J. Thomas, M.D., Postgraduate Student, Christian Medical College, Vellore-632 002, North Arcot District, Tamil Nadu, India; M. Joseph, M.B.B.S., Medical Officer; K. Ramanujam, M.B.B.S., formerly Consultant Physician, Schieffelin Leprosy Research & Training Centre, Karigiri, North Arcot District, Tamil Nadu, India; C. J. G. Chacko, M.D., Ph.D., Professor of Pathology; C. K. Job, M.D., F.A.M.S., F.R.C.Path., Professor of Pathology and Principal, Christian Medical College, Vellore-632 002, North Arcot District, Tamil Nadu, India.

TABLE 1. *Lepromin test—48 hr reaction.*

Classification	No. of patients	0-5 mm	6-10 mm	11-15 mm	16-20 mm	More than 20 mm
Tuberculoid	4	—	—	—	2	2
Borderline tuberculoid	12	6	—	2	2	2
Borderline lepromatous	4	3	1	—	—	—
Lepromatous	9	8	1	—	—	—
Indeterminate	9	5	2	2	—	—

When the reaction was oval or amoeboid in configuration, the diameters along the greatest dimension and at right angles to this were measured and the average value of the two readings recorded. The reactions were graded according to the criteria adopted by the VI International Leprosy Congress, Madrid, 1953 (10).

All reactions, whether positive or negative, were biopsied at 48 hr. The tissue was fixed in Formal-Zenker solution for 4 hr, transferred to 70% alcohol, routinely processed, and paraffin embedded. Five  $\mu$  sections were stained by the hematoxylin and eosin method and by the modified Fite-Faraco method for acid-fast bacilli (4). In the same patients the Mitsuda reaction was also assessed both clinically and histopathologically. These findings are being published separately (12).

### RESULTS

The ages of the patients studied ranged from nine years to 71 years. Thirty-one of them were males and seven females. The size of the early lepromin reaction in various groups of patients is shown in Table 1.

**Tuberculoid group. Clinical readings.** In the four patients belonging to this group, the diameter of the erythematous, infiltrated, early reaction ranged from 19.0 mm to 39.1 mm. Table 2 gives the correlation between the early and late lepromin reactions in this group.

**Histological reaction.** The extent and amount of the inflammatory reaction to lepromin was most marked in this group. These reactions were characterized histologically by pronounced hyperemia, extravasation of red cells, edema, and an intense inflammatory reaction involving the dermis and subcutis and in one patient, the epidermis as well. The cellular infiltrate consisted largely of lymphocytes, concentrated around blood vessels (Fig. 1), adnexal structures, arrectores pilorum muscles, and nerves. Phlebitis of the dermal veins was a conspicuous feature in two biopsies (Fig. 2). Moderate numbers of polymorphonuclear leukocytes were also present, diffusely infiltrating the dermis in the center of the reaction. Acid-fast bacilli were scarce and located within the neutrophils.

**Borderline tuberculoid group. Clinical**

TABLE 2. *Size and histology of the early and late lepromin skin test reactions in tuberculoid leprosy patients.*

Patient no.	Early reaction		Late reaction	
	Clinical reading in mm	Histological assessment (++) , (+) , ( $\pm$ ) , or (-) <sup>a</sup>	Clinical reading in mm	Histological assessment (+) or (-) <sup>b</sup>
1	19.0	++	8.0	+
2	22.0	++	11.7	+
3	23.3	++	21.6	+
4	39.1	++	15.0	+

<sup>a</sup> Early reaction (++) indicates dense lymphocytic infiltration; (+) indicates moderate lymphocytic infiltration; ( $\pm$ ) indicates minimal lymphocytic infiltration; early reaction (-) indicates absence of lymphocytes.

<sup>b</sup> Late reaction (+) indicates presence of epithelioid cell granuloma; late reaction (-) indicates absence of epithelioid cell granuloma.

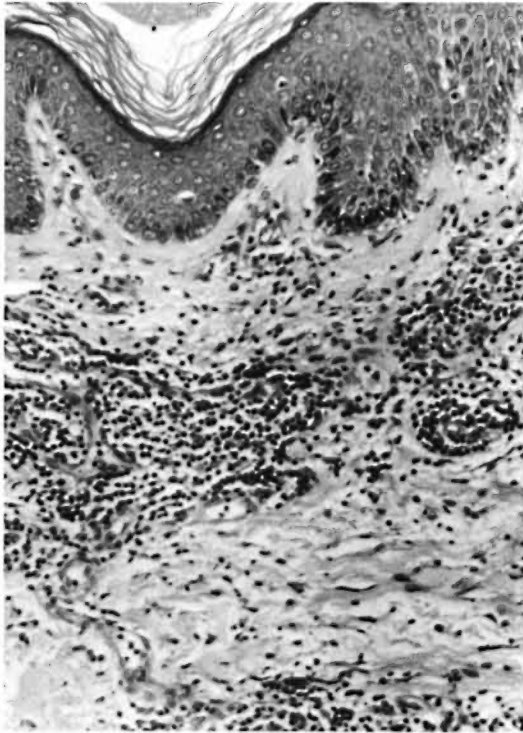


FIG. 1. Histological appearance of 48 hr lepromin in a tuberculoid (TT) patient. Note the dense collection of lymphocytes, mainly around blood vessels just beneath the epidermis. A few neutrophils can also be identified in the photomicrograph (H. & E.  $\times 480$ ).

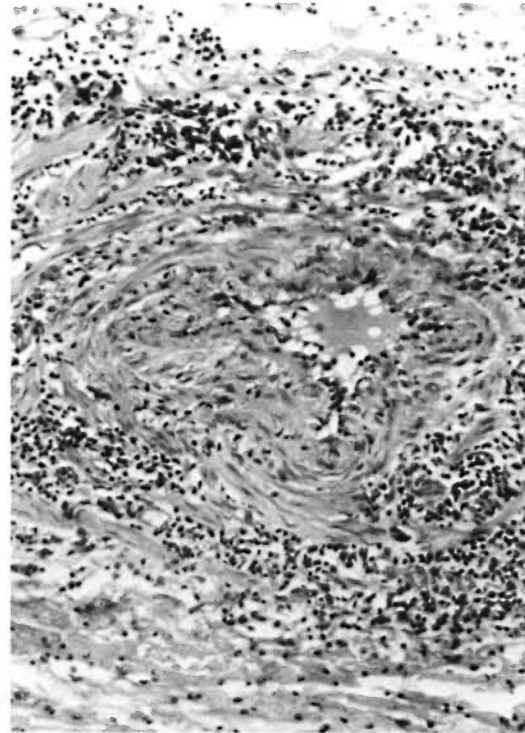


FIG. 2. Photomicrograph of a small subcutaneous vein in the 48 hr lepromin reaction of a tuberculoid (TT) patient. Note the edema and dense infiltration by lymphocytes of the wall of the vein and narrowing of the lumen (H. & E.  $\times 600$ ).

readings. There was no clinical reaction in three patients, induration less than 5.0 mm in size in three others, and in the remaining six, erythema and induration 11.75–23.5 mm in diameter. The readings of the early and late reactions are shown in Table 3.

**Histological reaction.** The inflammatory reaction was moderate in intensity in all of the 12 biopsies belonging to this group. The extent of the inflammation, degree of vascular dilatation, and edema were less pronounced as compared to the tuberculoid group. The inflammatory cells included a diffuse infiltrate of neutrophils and moderate numbers of perivascular lymphocytes (Fig. 3). A focal area of fibrinoid necrosis of the dermal connective tissue was observed in one patient. Fair numbers of the injected bacilli were detected, engulfed by the polymorphonuclear leukocytes.

**Borderline lepromatous group. Clinical readings.** The diameter of the early reac-

tion in the four patients ranged from 1.0 mm to 5.5 mm. Table 4 compares the early and late reactions in these patients.

**Histological reaction.** The degree of inflammatory reaction was mild to moderate in this group and comprised chiefly of polymorphonuclear leukocytes (Fig. 4). Lymphocytes were scarce and vascular changes and edema negligible. Numerous surviving acid-fast bacilli were identified within neutrophils, smooth muscle fibers, and extracellularly.

**Lepromatous group. Clinical readings.** Four of the nine patients demonstrated no clinical reaction. In four others, there was induration 1.0 to 3.0 mm in diameter. In one patient the reaction measured 6.1 mm in diameter. The readings of the early and late reactions are given in Table 5.

**Histological reaction.** As in the borderline lepromatous group, the cellular reaction was mild to moderate in intensity, and neu-

TABLE 3. Size and histology of the early and late lepromin skin test reactions in borderline tuberculoid leprosy patients.

Patient no.	Early reaction		Late reaction	
	Clinical reading in mm	Histological assessment (++) , (+) , (±) , or (-) <sup>a</sup>	Clinical reading in mm	Histological assessment (+) or (-) <sup>b</sup>
1	no reaction	+	3.0	+
2	no reaction	+	3.0	+
3	no reaction	+	6.0	+
4	2.0	+	5.3	+
5	2.0	+	10.5	+
6	4.5	+	9.0	+
7	11.75	+	8.9	+
8	12.75	+	4.5	+
9	15.6	+	7.4	+
10	18.5	+	18.0	+
11	23.0	+	9.7	+
12	23.5	+	5.6	+

<sup>a</sup> Early reaction (++) indicates dense lymphocytic infiltration; (+) indicates moderate lymphocytic infiltration; (±) indicates minimal lymphocytic infiltration; early reaction (-) indicates absence of lymphocytes.

<sup>b</sup> Late reaction (+) indicates presence of epithelioid cell granuloma; late reaction (-) indicates absence of epithelioid cell granuloma.

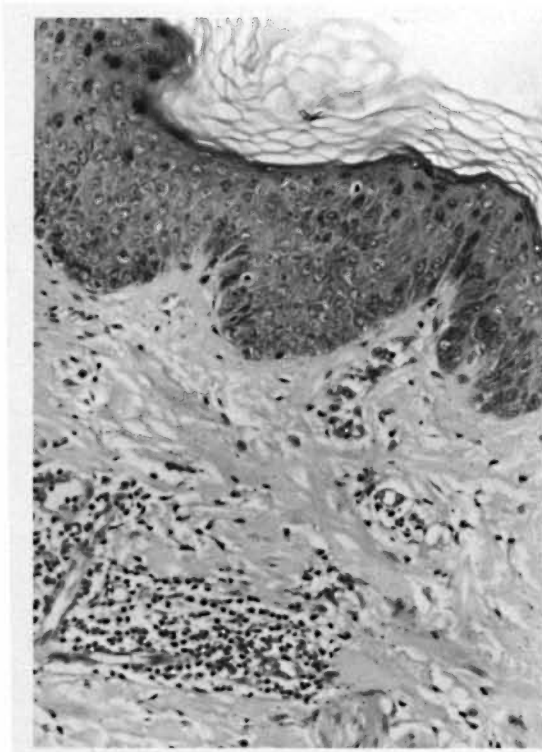


FIG. 3. Histological appearance of 48 hr lepromin in a borderline tuberculoid (BT) patient. Note the small collection of lymphocytes around blood vessels just beneath the epidermis. A few neutrophils are also present (H. & E.  $\times 480$ ).

trophils constituted the chief cell type. Karyorrhexis of the polymorphonuclear leukocytes was a notable feature. Lymphocytes were conspicuous by their absence. Acid-fast bacilli persisted in large numbers within neutrophils and extracellularly.

**Indeterminate group. Clinical readings.** There was no clinical reaction in two pa-

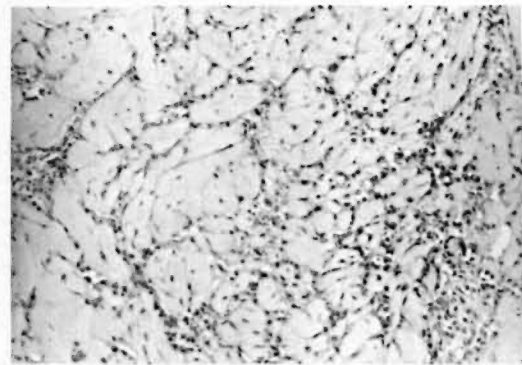


FIG. 4. Histological appearance of the 48 hr lepromin reaction in a borderline lepromatous (BL) patient. Note the diffuse infiltration of the subepidermal tissue by neutrophils. The tissue histiocytes and fibroblasts are prominent. Most of these neutrophils showed acid-fast bacilli in the acid-fast stain (H. & E.  $\times 600$ ).

TABLE 4. Size and histology of the early and late lepromin skin test reactions in borderline lepromatous leprosy patients.

Patient no.	Early reaction		Late reaction	
	Clinical reading in mm	Histological assessment (++) , (+) , (±) , or (-) <sup>a</sup>	Clinical reading in mm	Histological assessment (+) or (-) <sup>b</sup>
1	1.0	±	Less than 1.0	—
2	1.0	±	no reaction	—
3	2.0	±	no reaction	—
4	5.0	±	0.6 mm	—

<sup>a</sup> Early reaction (++) indicates dense lymphocytic infiltration; (+) indicates moderate lymphocytic infiltration; (±) indicates minimal lymphocytic infiltration; early reaction (-) indicates absence of lymphocytes.

<sup>b</sup> Late reaction (±) indicates presence of epithelioid cell granuloma; late reaction (-) indicates absence of epithelioid cell granuloma.

tients, reactions 1.0 to 7.1 mm in size were noted in five others, and erythematous infiltrated reactions 10.9–13.5 mm in diameter in the remaining two patients. Table 6 compares the early and late reactions in this group of patients.

**Histological reaction.** All nine patients showed a moderately dense inflammatory cell response which included neutrophils and many lymphocytes. Fair numbers of acid-fast bacilli persisted at the site of inoculation.

### DISCUSSION

Immunity to obligate intracellular parasites such as *Mycobacterium leprae*, *My-*

*cobacterium tuberculosis*, *Leishmania*, and certain fungi is dependent on cell-mediated immune mechanisms rather than serum antibodies (<sup>1</sup>). Delayed hypersensitivity, which is exemplified by a delayed cutaneous inflammatory response when certain soluble antigens are injected intradermally into sensitized animals, may be thought of as an *in vivo* model of the cell-mediated immune response (<sup>14</sup>). The classical example of delayed-type hypersensitivity is the tuberculin reaction (<sup>11</sup>). The early lepromin or Fernandez reaction, which closely resembles a delayed-type hypersensitivity reaction, is analogous to the tuberculin reaction (<sup>5</sup>). Unlike the tuberculin reaction the lep-

TABLE 5. Size and histology of the early and late lepromin skin test reactions in lepromatous leprosy patients.

Patient no.	Early reaction		Late reaction	
	Clinical reading in mm	Histological assessment (++) , (+) , (±) , or (-) <sup>a</sup>	Clinical reading in mm	Histological assessment (+) or (-) <sup>b</sup>
1	no reaction	—	no reaction	—
2	no reaction	—	no reaction	—
3	no reaction	—	no reaction	—
4	no reaction	—	less than 1.0	—
5	1.0	—	less than 1.0	—
6	1.0	—	no reaction	—
7	3.0	—	less than 1.0	—
8	3.0	—	no reaction	—
9	6.1	—	1.0	—

<sup>a</sup> Early reaction (++) indicates dense lymphocytic infiltration; (+) indicates moderate lymphocytic infiltration; (±) indicates minimal lymphocytic infiltration; early reaction (-) indicates absence of lymphocytes.

<sup>b</sup> Late reaction (+) indicates presence of epithelioid cell granuloma; late reaction (-) indicates absence of epithelioid cell granuloma.

TABLE 6. Size and histology of the early and late lepromin skin test reactions in indeterminate leprosy patients.

Patient no.	Early reaction		Late reaction	
	Clinical reading in mm	Histological assessment (+ +), (+), ( $\pm$ ), or (-) <sup>a</sup>	Clinical reading in mm	Histological assessment (+) or (-) <sup>b</sup>
1	no reaction	+	9.9	+
2	no reaction	+	3.1	+
3	1.0	+	6.5	+
4	1.0	+	6.9	+
5	3.0	+	15.5	+
6	5.1	+	6.5	+
7	7.1	+	7.8	+
8	10.9	+	no reaction	- <sup>c</sup>
9	13.5	+	8.5	+

<sup>a</sup> Early reaction (++) indicates dense lymphocytic infiltration; (+) indicates moderate lymphocytic infiltration; ( $\pm$ ) indicates minimal lymphocytic infiltration; early reaction (-) indicates absence of lymphocytes.

<sup>b</sup> Late reaction (+) indicates presence of epithelioid cell granuloma; late reaction (-) indicates absence of epithelioid cell granuloma.

<sup>c</sup> (?—biopsy missed the site of injection).

romin reaction has no diagnostic significance. It is, however, of great prognostic value since it indicates the ability of a leprosy patient to mount a cell-mediated immune response against *Mycobacterium leprae* (13).

The histological evaluation of the early lepromin reaction provides an understanding of the host tissue response to injected antigens of *M. leprae*. This study has shown that there is a quantitative and a qualitative difference in the character of the early inflammatory response to lepromin in the different groups of leprosy patients.

At the tuberculoid end of the spectrum the inflammatory reaction is maximum, and lymphocytes constitute the major cell type. In contrast, in the polar lepromatous group of patients, the extent and amount of inflammation are significantly lower, and the cellular infiltrate is chiefly polymorphonuclear in type. Lymphocytes are very scarce or absent.

In the borderline group the histology is intermediate in character with more lymphocytes in the borderline tuberculoid patients and fewer of these cells in patients closer to the lepromatous pole.

The histological reaction in the indeterminate group is comparable to that observed in borderline tuberculoid patients.

The outstanding feature of the histology of the Fernandez reaction is the inability of

patients belonging to the lepromatous spectrum to mobilize sensitized lymphocytes to the site containing the antigen. This is reflected in the absence of lymphocytic infiltration at the lepromin site. It is also noted that in these patients that the polymorphonuclear leukocytes persist at the site of injection and are associated with many acid-fast bacilli. The specific failure of the cell-mediated immune system in lepromatous patients results in their inability to destroy the injected bacilli by lymphocytes and macrophages. The persistence of the bacilli probably serves as a continuous chemotactic stimulus to attract polymorphonuclear leukocytes.

A comparison was also made between the clinical and histological appearance of early lepromin reactions. In the tuberculoid, lepromatous, and borderline lepromatous groups there was complete agreement between the two responses. In six of the 12 borderline tuberculoid patients and five of the nine patients belonging to the indeterminate group, the clinical reaction was less than 5.0 mm in diameter, but histologically, all of these patients showed a moderately dense inflammatory reaction, containing many lymphocytes. In an attempt to explain this discrepancy the depth of the cellular reaction in the dermis was evaluated in all biopsies. It was observed that in most of the above group of patients

the cellular infiltrate was localized predominantly in the mid or deep dermis. This finding could account for a false negative clinical reaction and emphasizes the importance of injecting the antigen into the upper dermis in order to insure accurate interpretation of the reaction.

In all the patients included in the study, the late or Mitsuda reaction was also evaluated clinically and histologically 21 days after injection of the antigen (<sup>12</sup>). A good correlation was found between the early and late histological reactions. A tuberculoid reaction was noted in the late lepromin biopsy in all patients with dense or moderate lymphocytic infiltration in the early biopsy, namely the tuberculoid, borderline tuberculoid, and indeterminate groups of patients.

However, as brought out in Tables 2 through 6, the agreement between the clinical readings of the early and late reaction was not absolute. In six patients with borderline tuberculoid leprosy and in five patients belonging to the indeterminate group, the early reactions were less than 5.0 mm in diameter whereas the late reaction varied from 3 to 15.5 mm in size.

This histological study confirms the value of the Fernandez reaction in reflecting the ability of a leprosy patient to mount a cell-mediated immune response against *Mycobacterium leprae*. Hence this reaction assumes great importance in the classification of patients with leprosy and in predicting the prognosis. Further, histological studies of the Fernandez reaction will be helpful in the evaluation of any procedure undertaken to enhance the immunity of an individual against *M. leprae*.

#### SUMMARY

The early lepromin reaction was studied clinically and histologically in 38 leprosy patients. There was a quantitative and a qualitative difference in the character of the early inflammatory response to lepromin in the different groups of leprosy patients. In tuberculoid patients, the extent and degree of inflammation and the density of lymphocytic infiltration were maximal. In the polar lepromatous group, the inflammatory reaction was far less intense, and lymphocytes were scarce or absent. An intermediate histology was noted in the borderline

and indeterminate groups of patients. In 11 patients with negative clinical reactions, the histology showed moderately dense lymphocytic infiltrations. The paucity of the clinical reaction could be due to the injection and localization of the antigen in the mid- and deep dermis. The correlation between early and late lepromin reactivity, both clinically and histologically, in the polar tuberculoid group and the polar lepromatous group was good. In the borderline and indeterminate groups, only the correlation between the early and late histological reactions to lepromin was good. The relationships between the early and late clinical reactions to lepromin showed marked variation. It is suggested that the early reaction is as good an indicator of lepromin reactivity as the late reaction in all forms of leprosy but only if it is assessed histologically.

#### RESUMEN

Se estudió clínica- e histológicamente la reacción temprana a la lepromina en 38 pacientes con lepra. Se encontraron diferencias cuantitativas y cualitativas en las respuestas inflamatorias tempranas entre los diferentes grupos de pacientes estudiados. En los tuberculoideos, el grado y la extensión de la inflamación y la densidad del infiltrado linfocítico fueron máximos. En el grupo lepromatoso polar, la reacción inflamatoria fue mucho menos intensa y los linfocitos fueron escasos o estuvieron ausentes. En los grupos de pacientes con lepra indeterminada e intermedia se notó una histología también intermedia.

En 11 pacientes con reacciones clínicamente negativas, la histología mostró infiltrados linfocíticos moderados. La ausencia de reacciones clínicas pudo haberse debido a la inyección (errónea) y localización del antígeno en la dérmis media y profunda.

La correlación entre las reactividades temprana y tardía a la lepromina fue buena en los grupos polares tuberculoide y lepromatoso tanto clínica- como histológicamente. En los grupos intermedio e indeterminado, sólo hubieron buenas correlaciones entre las reacciones temprana y tardía a la lepromina desde el punto de vista histológico ya que la correlación clínica entre dichas reacciones fue muy variable. Se sugiere que la reacción temprana es tan buen indicador de la reactividad a la lepromina como la reacción tardía pero sólo si se valora histológicamente.

#### RÉSUMÉ

Chez 38 malades de la lèpre, on a étudié cliniquement et histologiquement la réaction précoce à la lépromine. On a observé une différence, tant sur le plan quantitatif que qualitatif dans les caractères de la réponse inflammatoire précoce à la lépromine, dans les

différents groupes de malades de la lèpre. Chez les malades tuberculoïdes, l'étendue et le degré de l'inflammation, de même que la densité de l'infiltration lymphocytaire, étaient maximales. Dans le groupe lépromateux polaire, la réaction inflammatoire était beaucoup moins intense et les lymphocytes étaient rares ou absents. Dans les groupes de malades atteints de lèpre borderline ou indéterminée, on a relevé une histologie intermédiaire. Chez 11 malades présentant des réactions cliniques négatives, l'histologie témoignait d'infiltrations lymphocytaires de densité modérée. La faible réaction clinique pourrait être due à l'injection et à la localisation de l'antigène dans le derme moyen et dans le derme profond. La corrélation entre la réaction précoce à la lépromine et la réaction tardive, à la fois sur le plan clinique et sur le plan histologique, était satisfaisante dans le groupe tuberculoïde polaire et dans le groupe lépromateux polaire. Dans les groupes borderline et indéterminés seule la corrélation entre les réactions histologiques précoce et tardive à la lépromine étaient satisfaisantes. Les relations notées entre les réactions cliniques précoce et tardive à la lépromine ont montré des variations notables. On suggère que la réaction précoce constitue un indicateur aussi fidèle de la réactivité à la lépromine que la réaction tardive, dans toutes les formes de lèpre, mais à la condition toutefois que cette réaction soit étudiée du point de vue histologique.

#### REFERENCES

1. BRYCESON, A. D. M. Immunology of leprosy. *Lepr. Rev.* **47** (1976) 235-244.
2. DHARMENDRA. Immunological skin tests in leprosy. Part I. The isolation of protein antigen of *Mycobacterium leprae*. *Indian J. Med. Res.* **30** (1942) 1-7.
3. FERNANDEZ, J. M. M. The early reaction induced by lepromin. *Int. J. Lepr.* **8** (1940) 1-14.
4. FITE, G. L., CAMBRE, P. J. and TURNER, M. H. Procedure for demonstrating lepra bacilli in paraffin sections. *Arch. Pathol.* **43** (1947) 624-625.
5. HUMPHREY, J. H. and WHITE, R. G. Delayed-type hypersensitivity. In: *Immunology for Students of Medicine*. 3rd ed. Humphrey, J. H. and White, R. G., eds. Oxford and Edinburgh: The English Language Book Society and Blackwell Publications, 1970, 493-545.
6. Report of the WHO Expert Committee on Leprosy. *Int. J. Lepr.* **21** (1953) 531-535.
7. RIDLEY, D. S. and JOPLING, W. H. Classification of leprosy according to immunity. A five-group system. *Int. J. Lepr.* **34** (1966) 255-273.
8. RODRIGUEZ, J. N. Observations on lepromin (Mitsuda) reaction. *Int. J. Lepr.* **6** (1938) 11-32.
9. SCHUJMAN, S. Histopathology of the Mitsuda reaction in the various forms of leprosy. *Rev. Bras. Leprol.* **4** (1936) 469-478.
10. VI International Leprosy Congress, Madrid. Immunology—Lepromin reaction. *Int. J. Lepr.* **21** (1953) 531.
11. STEWART, F. S. Hypersensitivity. In: *Bacteriology and Immunology for Students of Medicine*. 9th ed. Stewart, F. S., ed. London: Baillière Tindall and Cassell, 1968, pp. 167-188.
12. THOMAS, J., JOSEPH, M., RAMANUJAM, K., CHACKO, C. J. G. and JOB, C. K. The histology of the Mitsuda reaction and its significance. *Lepr. Rev.* **51** (1980) 329-339.
13. TURK, J. L. Cell-mediated immunological process in leprosy. *Bull. WHO* **41** (1969) 779-792.
14. WING, E. J. and REMINGTON, M. D. Delayed hypersensitivity and macrophage functions. In: *Basic and Clinical Immunology*. 2nd ed. Fudenberg, H. H., Stites, D. P., Caldwell, J. L. and Wells, J. V., eds. Los Altos, California: Lange Medical Publications, 1978, pp. 96-109.