

Lepromatous Leprosy Clinically Localized to One-Half of the Face. Report of a Case¹

Jose M. Mascaró, Juan Ferrando, and Rosa Gratacos²

A Negro male, 28 years of age, born in the Cameroons, with no relevant family or personal history, presented himself in the outpatient section of the Department of Dermatology (Faculty of Medicine of Barcelona) on 21 April 1980. Eighteen months previously he had noticed an eruption of papular lesions, first affecting the left upper eyelid and then progressing to the left cheek and the left side of the forehead. A diagnosis of xanthomatosis had previously been made.

Dermatological examination. On the left side of the face, multiple hemispheric papules of 1 to 5 mm in diameter were seen (Fig. 1). Their surface was smooth and shiny with some telangiectasiae. The color was lighter than the unaffected skin. No clinical abnormality of the peripheral nerves was seen. Different clinical diagnoses were discussed: molluscum contagiosum, leishmaniasis, lepromatous leprosy, and xanthomatosis.

General examination. The liver was enlarged to about three finger breadths below the costal margin.

Laboratory. Eosinophilia (19%) was noted. Serum protein electrophoresis showed 32% of the total protein (7.1 g/dl) to be gamma globulin. *Lambli* *intestinalis* were found in the stool.

Other examinations. The lesions were anesthetic. On three occasions *M. leprae* were not found in the nasal mucus and ear lobe dermal scrapings. The Fernandez and Mitsuda reactions were negative. Intradermal tests for delayed hypersensitivity (Candida and PPD) were also negative. The triple histamine test (Lewis) showed a normal

response on the forearm while in the affected skin the axon-dependent erythema was absent. Sweating was absent in the lesions and in the apparently normal skin of the left side of the face.

Electromyography of facial muscles and a study of the motor nerve conductivity of the facial and ulnar nerves showed asynchronism of the electric potential of both facial nerves (pattern of demyelination) while the response in the ulnar nerves was normal.

Skin scrapings from the right hemiface were negative for acid-fast bacilli on three occasions. In spite of this a biopsy of preauricular clinically unaffected skin on the right side showed small but clear leproma-

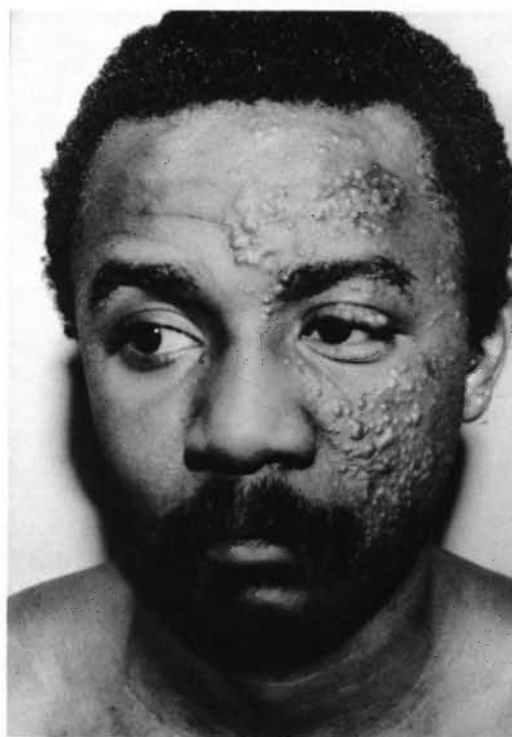

FIG. 1. Multiple papules clinically localized on the left side of the face.

¹ Received for publication on 28 November 1980; accepted for publication in revised form on 4 June 1981.

² J. M. Mascaró, M.D., M.S., Professor and Chairman of Dermatology; J. Ferrando, M.D., Associate Professor of Dermatology; R. Gratacos, M.D., Resident in Dermatology, Central University of Barcelona Medical School, Barcelona, Spain.

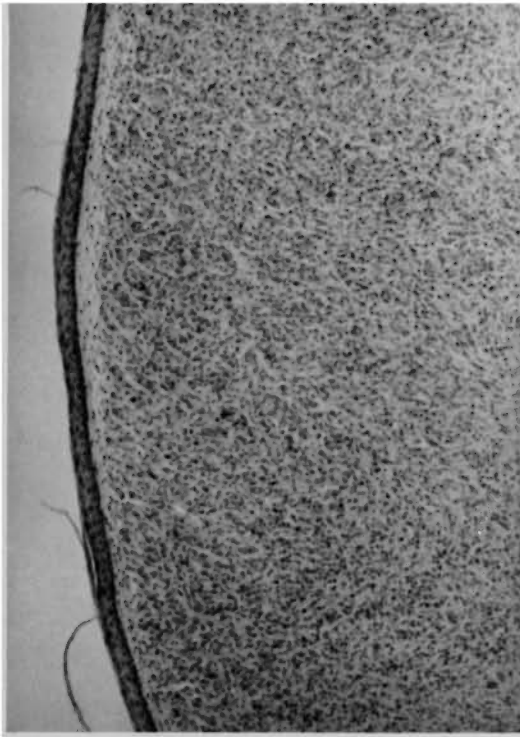


FIG. 2. Dense infiltrate of the dermis essentially made up of large, clear cells with foamy cytoplasm. Note the subepithelial band of Unna. (H. & E., original magnification $\times 120$.)

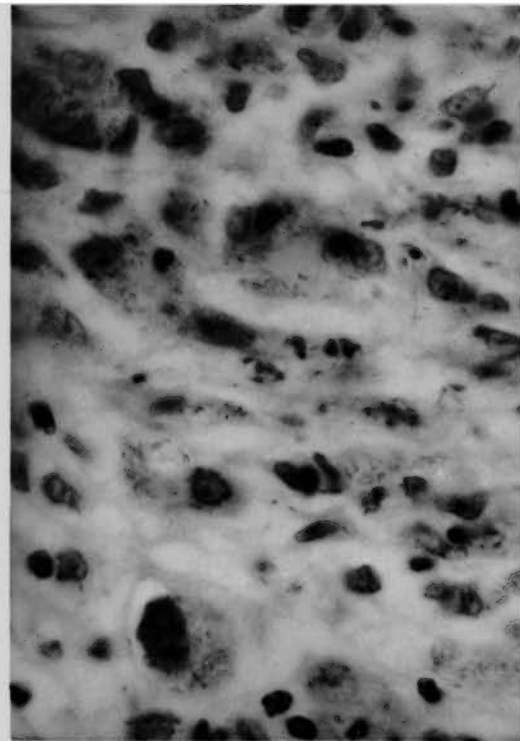


FIG. 3. Ziehl-Neelsen stain. A great number of intracytoplasmic acid-fast bacilli arranged in globi. (Original magnification $\times 120$.)

tous leprosy infiltrates and the presence of *M. leprae*.

Histopathology. The epidermis was thinned and rete pegs were absent. A dense infiltrate occupied the dermis sparing the subepithelial zone (Fig. 2). The infiltrate surrounding the nerves and the appendages essentially consisted of large, clear cells with foamy cytoplasm. Scarce lymphocytes and plasma cells were also seen. The Ziehl-Neelsen stain showed a great number of acid-fast bacilli arranged in globi (Fig. 3).

Comment. This case is of interest because of the peculiar distribution of the lesions of lepromatous leprosy. The lesions were confined to the left hemifacial area in a patient who had no leprosy bacilli in the nasal mucus and in the ear lobe scrapings. We have found no other report of a similar clinical distribution. At first we speculated that this peculiar distribution could be due to an extension of the infection through the nerves on one side of the face. The histological involvement of clinically unaffected skin, however, changes our question. Why

was the involvement of the skin only clinically developed in one-half of the face?

SUMMARY

A case of lepromatous leprosy with lesions clinically localized to the left hemifacial area in a 28-year old Negro male is reported. The peculiarity of this case was the distribution of the lesions. The histopathology and other examinations showed typical lepromatous leprosy.

RESUMEN

Se presenta un caso de lepra lepromatosa con lesiones localizadas en el área hemifacial izquierda en un paciente Negro de 28 años de edad. Lo peculiar de este caso fue la distribución de las lesiones. La histopatología y otros exámenes fueron típicos de la lepra lepromatosa.

RÉSUMÉ

On relate ici un cas de lèpre lépromateuse avec lésions cliniques localisées à l'hémiface gauche, chez un sujet de race noire, âgé de 28 ans. La particularité de ce cas en était la distribution caractéristique des lésions. Les examens histopathologiques et autres ont révélé une lèpre lépromateuse typique.