

INTERNATIONAL JOURNAL OF LEPROSY

And Other Mycobacterial Diseases

VOLUME 49, NUMBER 4

DECEMBER 1981

The Histological Course of Reactions in Borderline Leprosy and Their Outcome¹

Dennis S. Ridley and K. B. Radia²

There is a well recognized group of reactions (Jopling Type 1) which is most characteristic of borderline leprosy, since in all cases the patients enter the BL-BT zone of the spectrum either before, during, or after the reaction. The earlier literature is considerably confused by problems of nomenclature and classification and by the variable outcome of the reactions (^{24, 25}). They are usually beneficial and may be associated with lepromin conversion from negative to positive, though it is not always sustained, and by elimination of bacilli (^{8, 11, 19, 20, 21}). They have therefore been widely known as reversal reactions (²⁴), though the term does not express the concept of downgrading as well as upgrading within the spectrum (¹⁶). These reactions are essentially an expression of immunological instability (¹⁶) associated with a sharp though temporary rise in the lymphocyte transformation ratio (^{3, 5, 13}) which suggests a form of delayed hypersensitivity (^{4, 17}). In immunologically deficient mice, re-

actions of this type, with a shift towards the tuberculoid pole (upgrading), can be induced by lymphocyte replacement (¹⁵) or thymus implant (¹²). Reactions associated with downgrading towards the lepromatous pole are unusual, though they have been described clinically (²⁶) and their existence needs to be recognized. The shift in classification observed in skin lesions is associated with parallel changes in lymph nodes (²⁷).

Despite the confusion of the older literature, there has been remarkably little written about these reactions in the last 20 years, mainly due to the ethical need to suppress such reactions. They have never received a full histological description. In the present paper the histological course of the reactions is described in a limited number of cases in which it was possible to follow the outcome.

MATERIAL AND METHODS

Patients. Twelve cases, for which clinical documentation and biopsy were available, were picked out from past records on the following grounds: 1) the patients were in reaction clinically and histologically; 2) they were at some time classified within the borderline region (BT, BB, BL), either before, during, or after the reaction; and 3) data was available, either clinical or histo-

¹ Received for publication on 2 April 1981; accepted for publication on 10 August 1981.

² D. S. Ridley, M.D., Consultant Pathologist, Hospital for Tropical Diseases, London NW1 0PE, England; K. B. Radia, M.B.Ch.B., M.R.C. Path., Department of Histopathology, Medical School, Kenyatta National Hospital, University of Nairobi, P.O. Box 30588, Nairobi, Kenya.

logical, of events leading up to or following the reaction. Eleven of the twelve patients had received less than 6 months' treatment at the onset of the reaction.

The biopsies had been referred to this hospital from the Medical Research Council Units in Sungei Buloh, Malaysia (5 cases), or in Addis Ababa (4 cases), or from stations elsewhere in Africa (2 cases); one patient was of Eurasian origin. In all, there were 33 biopsies for the 12 cases, which were re-examined in the light of the most recent available data. The precise time sequence of the reactions was not known in all cases, but it was possible to piece together the order of events in all and the duration in some.

RESULTS

The 12 patients were selected as being in reaction both clinically and histologically so that correlation between these two aspects was axiomatic. However, among the rejected cases, correlation in some was poor. There was clinical reaction but only slight histological signs of it, or histological reaction with no clinical counterpart. (Some but not all of these patients may have been on anti-inflammatory drugs.)

The 12 reactions were categorized as follows:

a) Upgrading (reversal) reactions, 8 cases. Upgrading of the patient's classification was observed in a follow-up biopsy taken within 6 months of the first biopsy (7 cases); or there was a sharp fall in the bacterial index in the granuloma (8 cases). The mean fall in the index was 2.75 (i.e., about 500 fold), and in four cases the follow-up biopsy was bacteriologically negative. A later biopsy showed complete resolution or non-specific inflammation in three cases. The longest period of treatment before the onset of the reaction was 5 months. All the patients had received some treatment, though one had abandoned it at the time of onset.

b) Downgrading reactions, 2 cases. The patients were reported to be downgrading clinically at the time of onset of the reaction, and a follow-up biopsy confirmed downgrading of the classification histologically (2 cases). This biopsy also showed a rise in the bacterial index of the granuloma

in each case (mean 1.5). One patient was untreated at the time of onset, and in the other the onset was within 3 months of commencing treatment.

c) No change or static reactions, 2 cases. Clinically there was a flare-up of new lesions which in one case was interpreted as persistent activity, and in the other as downgrading to BL, neither of which was confirmed histologically. Follow-up biopsy showed no definite change in the classification and no significant alteration (<1) in the bacterial index. Bacilli were not eliminated in either case. One patient had received 19 months' treatment; the other was untreated and 3 months post-partum.

Upgrading reactions. Biopsies of the eight cases illustrated the histological sequence of events throughout the course of the reaction, which can be described in four stages, though they are in no way definitive. There was some overlap, and not all the features described were found in every case.

1) Incipient or early reactions, which may precede or be accompanied by reaction, usually showed mild edema with dilatation of the lymphatics in the superficial dermis and perhaps a loosening of the collagen bundles in some areas. There was sometimes a diffuse proliferation of fibrocytes between the collagen bundles throughout the dermis, which was otherwise normal. The granuloma was not significantly affected. Lymphocytes were always present at the onset, not necessarily numerous, but increased by comparison with the pre-reaction biopsy.

2) Acute stage reactions were sometimes characterized mainly by a more profuse edema, which might involve the dermis, the perigranulomatous zones, or the granuloma itself. Especially in the latter case there was separation of granuloma cells and some disorganization of its swollen structure. Some maturation of granuloma cells might or might not have occurred. Lymphocytes were fewer than in the early stage. There was proliferation of fibroblasts, which was most intense around the periphery of the granuloma, causing the formation of spurs which were sometimes more conspicuous than in uncomplicated active lesions. Elastosis was sometimes present.

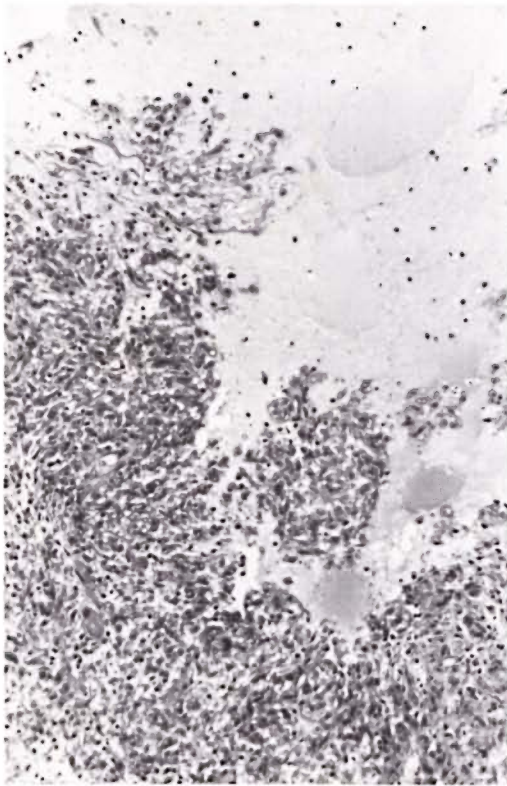


FIG. 1. Acute stage upgrading reaction with necrosis and liquefaction of granuloma (H&E $\times 120$)

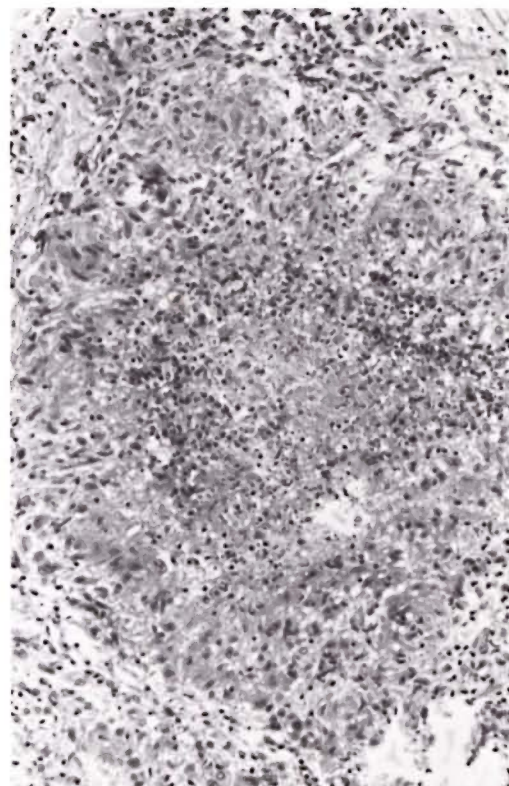


FIG. 2. Acute stage upgrading reaction. Necrotic center with polymorphs surrounded by immature epithelioid cells. (H&E $\times 120$)

In three severe cases the acute stage was marked by overt necrosis (Fig. 1). In one there was extensive breakdown and liquefaction of some parts of the granuloma, though elsewhere the granuloma had not altered since the beginning of the reaction. In another case there were small necrotic centers with nuclear pyknosis. In the third case there were many larger necrotic centers, with polymorphs, surrounded by palisading of immature epithelioid cells with a few small giant cells (Fig. 2). Although clinically this case was thought to be erythema nodosum leprosum (ENL), the histology was distinctive and so was the outcome of the reaction. In less severe reactions the acute stage may have been marked by necrosis of isolated granuloma cells.

3) The late stage showed tuberculoid features, regardless of the initial classification. The lesion differed from that of non-reacting BT or TT in the formation of well defined organized clusters of mature epithelioid cells (Fig. 3), or at least small whorls

of cells (Fig. 4) and in the large number of giant cells. These were at first small and nondescript; later there were larger giant cells among them which might be of the foreign body or Langhans' type. The latter persisted after the reaction subsided if the lesion did not resolve. The number of lymphocytes was unchanged. Fibroblasts or fibrosis might be seen.

4) The resolving stage after an intense reaction with strong upgrading was characterized by areas of fibrinoid necrosis (Fig. 5) with heavy proliferation of fibroblasts and fibrocytes and occasionally the formation of keloid-like bands of fibrous tissue (Fig. 6). In one case vasculitis with extravasated blood pigment was present. In most cases the reaction subsided without severe fibrosis. The granuloma gave place to non-specific infiltrate. Or, if it persisted, it assumed the usual features of a BT or TT lesion.

The time sequence of these phases varied

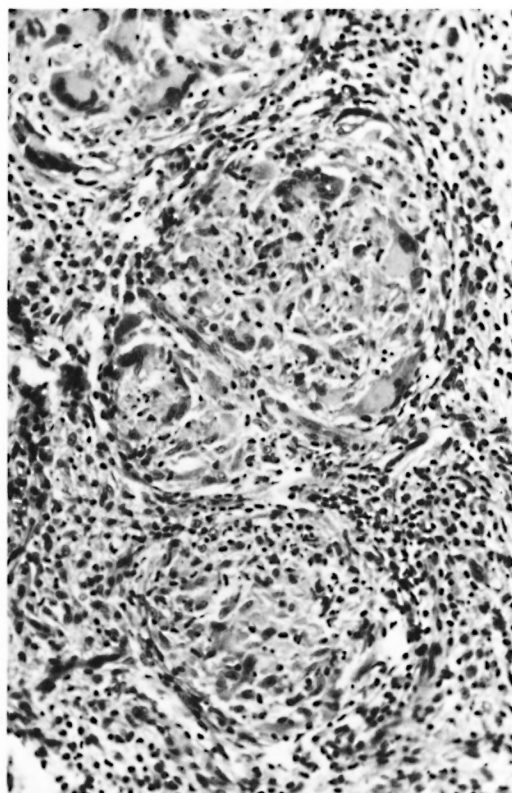


FIG. 3. Late stage upgrading reaction. Organized cluster of epithelioid cells and undifferentiated giant cells. (H&E $\times 200$)

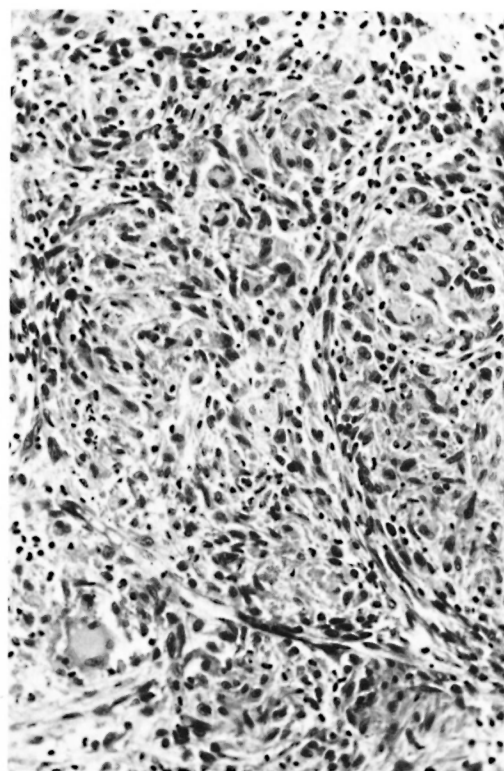


FIG. 4. Late stage upgrading reaction. Small whorls of epithelioid cells. (H&E $\times 200$)

considerably, depending mainly on the initial pre-reaction classification. A BL or LLs patient might go through stages 1 and 2 only, or he might progress through each stage over a period of a few months. A patient who was initially BT might go straight from stage 1 to 3, or he might start his reaction at stage 3 and perhaps terminate it there.

Downgrading reactions. The two patients before the onset of the reaction were classified as BT clinically and histologically, though the bacterial load would have been more appropriate for BB.

The reactions were characterized histologically by moderate or fairly severe edema (Figs. 7 and 8) in and around the granuloma, which became considerably swollen by cellular increase as well as by the edema. The epithelioid cells gave place to macrophages, at first in local areas so that the lesion was at this stage truly "dimor-

phous." Later macrophages became general, the bacterial load increased, and the patients were classified as BL. Giant cells were not conspicuous. Lymphocytes were fewer than in early upgrading reactions. Diffuse fibrocytosis appeared in the collagen of the unaffected dermis in one case. (In the other the whole dermis was occupied by granuloma.)

Static reactions. One of the two patients was classified initially as LLs, the other as BT.

Histologically edema was slight. The reaction was characterized by the appearance of a number of small giant cells which had not previously been present. In the BT case these took the form of poorly developed Langhans' cells, though the granuloma was sparse and notably lacking in mature epithelioid cells. Lymphocytes were present. In the unaffected dermis there was fibrocytosis and elastosis or fibrosis (Fig. 9). There was no significant change in classification as a result of the reaction. A com-

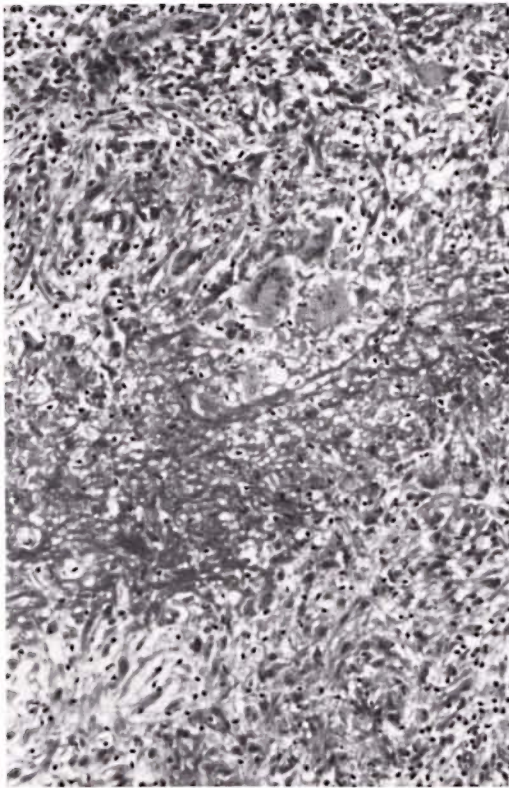


FIG. 5. Unusually severe fibrinoid necrosis in the resolving (fibrosing) stage of an upgrading reaction. Note that the giant cells are associated with this necrosis, not with the granuloma. (H&E $\times 150$)

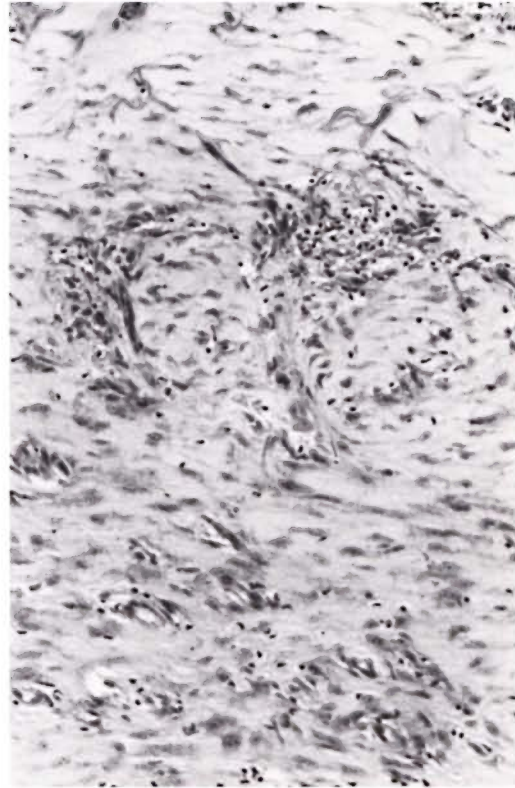

FIG. 6. Resolving stage (same section as Fig. 5). Fibroblast proliferation, below; fibrocytosis and fibrosis, above. (H&E $\times 150$)

parison with biopsies of upgrading and downgrading reactions suggested that these two static reactions represented ineffective attempts at upgrading.

Mast cells were not a constant finding in any of these forms of reaction and eosinophils were seldom seen. Plasma cells were present in about the same numbers as in non-reacting lesions of the same type.

DISCUSSION

The borderline region of the leprosy spectrum is generally accepted as being immunologically unstable. It would appear that reactions of the type reported here represent episodes of hypersensitivity which are precipitated a) by an increase of antigen due to bacterial multiplication in a patient who retains some degree of hypersensitivity, or b) by an immunological uncovering of antigen which was not previously de-

tected, or c) by an improvement in the patient's immunological performance due either to therapy or constitutional factors (e.g., post-partum recovery of immunity, ⁽¹⁸⁾). At the onset of the reaction, the outcome could not be predicted histologically, nor were clinical impressions always reliable. It is doubtful whether at this stage the outcome has yet been determined. It probably rests on systemic factors which cannot be determined by the examination of individual lesions: the total antigenic load in the body (detected and undetected), the performance of the lymphocyte system, and antigen-antibody ratio. A downgrading reaction can be followed by reversal if circumstances change or vice versa. Whatever the type of reaction the first sign was edema.

Later in the reaction regrading became apparent, even if there was no pre-reaction biopsy for comparison. The best sign of up-

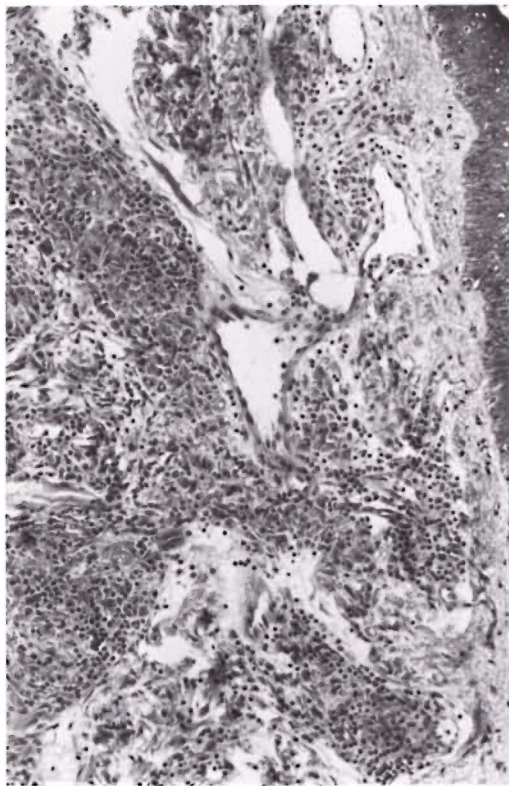


FIG. 7. Downgrading reaction with dilated lymphatics (which could equally be an early upgrading reaction). (H&E $\times 120$)

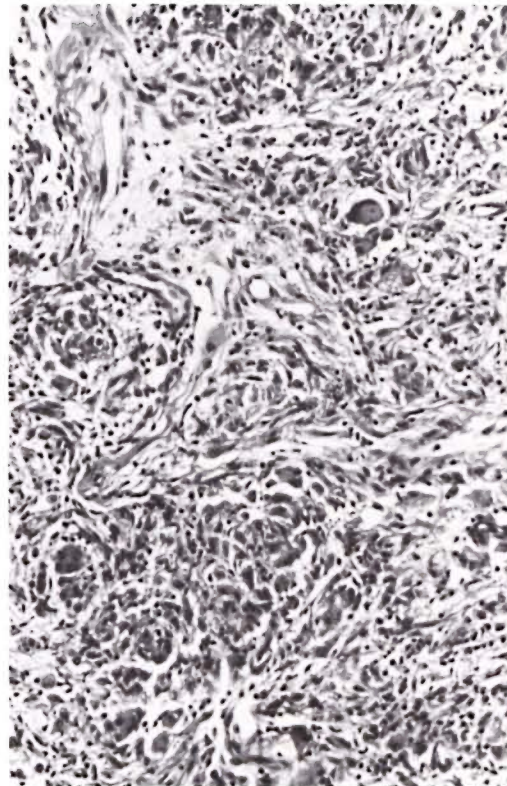


FIG. 8. Downgrading reaction with marked edema in and around the granuloma (which could equally be an acute stage upgrading reaction). (H&E $\times 150$)

grading in the majority of cases was the formation of whorls or small nests of well developed epithelioid cells. Maturation or differentiation of epithelioid cells is indicated by a fairly large nucleus with margination of chromatin and a prominent eosinophilic nucleolus (¹). Later the whole cell may enlarge, but this is not usually seen during the reaction. Other signs of strong upgrading which were present in a few cases were erosion of the epidermis by granuloma and fibrinoid necrosis in the collagen of the dermis. Giant cell formation usually occurred in the late stage of the reaction. It is known that giant cells may be a response to necrosis irrespective of the form of hypersensitivity (¹⁴). This is probably the explanation here, the necrosis being either of granuloma cells or collagen, in which case the giant cells presumably signify no more than healing. During the reaction, the form of the giant cells appeared not to be very useful as regards pre-

diction of the outcome, and there was the problem of differentiating them from those that were present before the onset. After the signs of reaction had subsided the giant cells, if they persisted, assumed the form characteristic of the new position in the spectrum, e.g., large Langhans' cells in TT (⁵). Necrosis was occasionally associated with a polymorphonuclear infiltrate.

Downgrading reactions produced edema similar to that of an upgrading reaction, but lymphocytes were fewer. Giant cells were not conspicuous, though it is not certain if this is always the case. The outcome was denoted by an increase of macrophages intermingled with residual immature unorganized epithelioid cells. However, more experience is needed of both downgrading and static forms of reaction. It is not established that either of them is ever sufficiently severe to produce overt necrosis. It may be noted that lymphocytes were a feature of the early stage of borderline reactions,

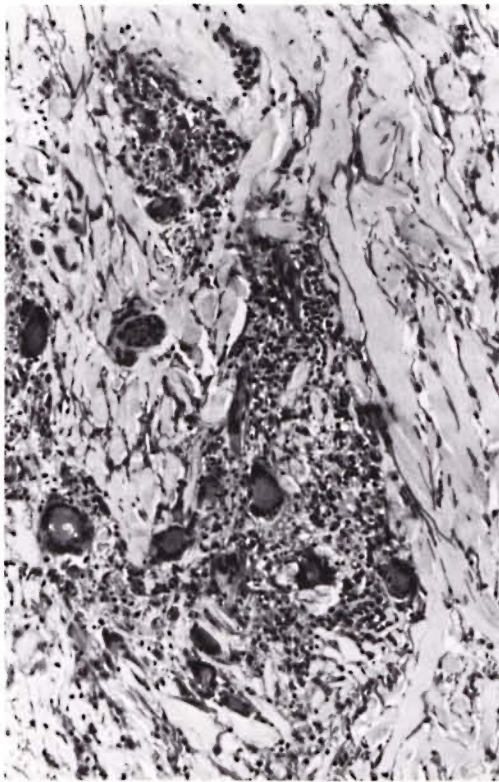


FIG. 9. Late stage static reaction with prominent giant cells though little granuloma, and elastosis in the dermis. (H&E $\times 120$)

whereas in ENL they are a late stage phenomenon.

It is interesting that all the 12 cases in the present study were bacteriologically positive at the onset of the reaction, though four of them were classified BT, a group in which bacilli are often hard to demonstrate. Souza Campos and de Souza⁽¹⁹⁾ found that "reactional tuberculoid" cases were always bacteriologically positive, a point of distinction from "tuberculoid reactivation." This is consistent with the view that the reaction is due to an excess of antigen in relation to the level of hypersensitivity. However, two other biopsies of BT patients in reaction in our collection were bacteriologically negative, and both were considered clinically to be downgrading. (These cases were excluded from the study as follow-up was not possible.) Some workers have found lipids present in some of these reactions, though not in cases of comparable classification without reaction^(7,9).

These lipids have been found to be of value in classifying the reactions, and possibly of prognostic significance (Prof. R. D. Azulay and Prof. R. Garrido Neves, 1980, personal communication). They might be attributable to destruction of mycobacteria or their host cells.

During the reaction the lymphocyte responsiveness is enhanced instead of inhibited by a plasma factor, though it is not known whether this is primary or secondary⁽⁴⁾. The immunological mechanisms are obviously complex. Nevertheless, it may be that these reactions are essentially similar to tuberculin or lepromin⁽²³⁾ reactions taking place sequentially at multiple sites where mycobacterial antigen becomes exposed. The temporary swelling of the granuloma, even in upgrading reactions which eventually resolve completely, indicates that there must be a fresh influx of mononuclear cells in the early stage of the reaction, as in tuberculin reactions. Lymphocytes are present but polymorphs are scanty. The time required for the evolution of epithelioid cells is about the same—14 days or more⁽¹⁴⁾. In each case the giant cells are at first of the foreign body type, later evolving perhaps as Langhans' cells if the lesion does not first resolve⁽¹⁴⁾. In each case the hypersensitivity response causes a disturbance of collagen due to accumulation of fluid in the early stage⁽⁶⁾. The parallel with the tuberculin reaction would be better in the case of a reactive BT patient than in BL or LLs, but there appears to be no absolute point of distinction between the two. In the latter the level of hypersensitivity is lower, but antigen is more abundant and the reaction is less dependent on unmasking.

In the present state of knowledge there is a certain gap between artificially induced skin test reactions which are the model of delayed type hypersensitivity and granulomatous lesions which develop in the course of natural infections caused by the same antigenic agents. The reactions of borderline leprosy, due to the quirk of the delayed recognition of antigen in protected sites, or to the recovery of hypersensitivity after treatment, may to some extent fill this gap. Whether or not "granulomatous hypersensitivity" is an entity, its relationship

to delayed hypersensitivity, or to Coombs and Gell Type IV reactions, has not been clearly elucidated (^{2,10}). The outcome in leprosy may be either a "weak" granuloma (BT) or a "strong" granuloma (TT), the histological features of which correlate with the lymphocyte transformation ratio (⁵). The granulomatous response is undoubtedly enhanced by the hypersensitivity, but it is not yet established that it is quantitatively different from that produced by strong irritants, including certain mycobacterial fractions (²²), in the absence of hypersensitivity.

SUMMARY

The histological course and the outcome of reactions was followed in 12 patients who were all in the borderline (BT-BL) zone of the spectrum at some time during the reaction. In eight patients the reaction proved to be of the upgrading or reversal type with a shift in classification toward the tuberculoid pole. In two patients the reaction was of the opposite downgrading type, and in two there was no significant change in classification as a result of the reaction.

Early reactions were characterized by edema and an increase in the number of lymphocytes which was more marked in upgrading than downgrading reactions, but at this stage the outcome could not be reliably predicted. In the acute stage necrosis was apparent in severe cases and was followed by giant cell formation and the evolution of the granuloma cells depending on the direction of the shift: organized clusters of mature epithelioid cells in upgrading, macrophages in downgrading. At all stages the collagen of the dermis might be involved in varying degree, which in extreme cases included fibrinoid necrosis and scarring in the late stage.

The histology is compared to that of tuberculin reactions. All cases were bacteriologically positive at the onset of the reaction. The results were consistent with the view that these reactions are delayed type hypersensitivity phenomena associated with the unmasking of bacterial antigen in nerve or other protected sites, or with an increase of hypersensitivity as a result of treatment. They demonstrate the evolution of a granuloma in mycobacterial disease.

RESUMEN

Se siguió el curso histológico y las consecuencias de las reacciones leprosas en 12 pacientes con lepra intermedia (BT-BL). En ocho pacientes, la reacción fue del tipo reverso con un cambio en la clasificación hacia el extremo tuberculoide. En dos pacientes la reacción fue del tipo opuesto y en dos no hubo un cambio significativo en su clasificación como resultado de la reacción.

Las reacciones tempranas se caracterizaron por la presencia de edema y por un incremento en el número de linfocitos que fue más evidente en las reacciones reversas, pero a este nivel el resultado no pudo predecirse de manera confiable. En la etapa aguda de las reacciones, la necrosis fue aparente en los casos severos y fue seguida por la aparición de células gigantes; la evolución de las células del granuloma dependió de la dirección del cambio: grupos organizados de células epitelioides maduras en las reacciones reversas y macrófagos en las otras. En todos los estadios de la reacción, la colágena de la dermis estuvo afectada en diferentes grados; en los casos extremos hubo necrosis fibrinoide y cicatrización en las etapas tardías.

Se compara la histología de las reacciones con aquella de las reacciones a la tuberculina. Todos los casos fueron bacteriológicamente positivos al inicio de la reacción. Los resultados fueron consistentes con el concepto de que estas reacciones representan fenómenos de hipersensibilidad del tipo tardío asociados con la exposición de antígenos bacterianos en los nervios o en otros sitios protegidos, o con un incremento de la hipersensibilidad como resultado del tratamiento. Los resultados nos mostraron la evolución de un granuloma en enfermedades micobacterianas.

RÉSUMÉ

Chez 12 malades atteints de réaction lépreuse, et dont pour tous la maladie s'est située à un certain moment de la réaction dans la zone borderline (BT-BL) du spectre on a suivi l'évolution histologique et l'issue des réactions. Chez 8 de ces malades, la réaction s'est révélée être du type inverse (reversal), ou du type de récupération (upgrading) avec un classement dans la classification qui glissait vers le pôle tuberculoïde. Chez deux malades, la réaction était, à l'opposé, du type de dégradation (downgrading) et chez deux malades on n'a enregistré aucune modification dans la classification à la suite de cette réaction.

Les réactions précoces étaient caractérisées par de l'oedème et par une augmentation dans le nombre de lymphocytes, qui était plus marquée dans les réactions de récupération (upgrading) que dans les réactions de dégradation (downgrading); toutefois, à ce stade, l'issue de la réaction ne pouvait pas être prédite de manière valable. Au stade aigu, on a observé de la nécrose dans les cas graves, celles-ci étant suivies de

formation de cellules géantes, et d'une évolution des cellules du granulôme qui était sous la dépendance de la direction notée dans le glissement de classification, à savoir une évolution vers l'organisation d'amas de cellules épithélioïdes bien développées dans la réaction de récupération, et l'apparition de macrophages dans la réaction de dégradation. A toutes ces étapes, le collagène du derme peut être impliqué à divers degrés, et ceci dans les cas extrêmes comprend même l'apparition de nécrose fibrinoïde, et dans une étape ultérieure, de cicatrisation.

L'histologie a été comparée à celle observée dans les réactions à la tuberculine. Tous les cas étaient bactériologiquement positifs au début de la réaction. Les résultats étaient en accord avec l'opinion qui veut que ces réactions constituent des phénomènes du type de l'hypersensibilité retardée, associés avec l'apparition d'antigènes bactériens dans les nerfs et dans les autres sites protégés, ou bien témoignent d'une augmentation de l'hypersensibilité suite au traitement. Ces résultats illustrent l'évolution du granulôme dans la maladie micro-bactérienne.

Acknowledgments. We are grateful to Dr. W. H. Jopling, Dr. A. B. G. Laing, Dr. J. M. H. Pearson, Dr. M. F. R. Waters, and others who kindly sent us biopsies and supplied clinical data. Dr. Radia received financial support from UNDP/World Bank/WHO Special Programme for Research and Training in Tropical Diseases.

REFERENCES

- ADAMS, D. O. The structure of mononuclear phagocytes differentiating *in vitro*. *Amer. J. Path.* **76** (1974) 17-48.
- ADAMS, D. O. The granulomatous inflammatory response. *Amer. J. Path.* **84** (1976) 164-188.
- BARNETSON, R. ST. C., BJUNE, G., PEARSON, J. M. H. and KRONVALL, G. Antigenic heterogeneity in patients with reactions in borderline leprosy. *Brit. Med. J.* **4** (1975) 435-437.
- BJUNE, G. and BARNETSON, R. ST. C. Plasma factors in delayed-type hypersensitivity. Augmentation of lymphocyte responses in borderline leprosy reactions. *Clin. Exp. Immunol.* **26** (1976) 397-402.
- BJUNE, G., BARNETSON, R. ST. C., RIDLEY, D. S. and KRONVALL, G. Lymphocyte transformation test in leprosy; correlation of the response with inflammation of lesions. *Clin. Exp. Immunol.* **25** (1976) 85-94.
- BLACK, S., HUMPHREY, J. H. and NIVEN, J. S. F. Inhibition of Mantoux reaction by direct suggestion under hypnosis. *Brit. Med. J.* **1** (1963) 1649-1652.
- CAMPOS, R. DE C. J. Lipoids in the reactional tuberculoid leprosy granuloma. *Int. J. Lepr.* **18** (1950) 155-160.
- CHASSINAND, R., DESTOMBES, P. and BOURCART, N. Transformation en lèpre tuberculoïde de deux cas de lèpre indéterminée prélépromateuse au cours d'un état de réaction. *Int. J. Lepr.* **28** (1960) 224-232.
- DAVISON, A. R., KOOLJ, R. and WAINWRIGHT, J. Classification of leprosy. II. The value of fat staining in classification. *Int. J. Lepr.* **28** (1960) 126-132.
- EPSTEIN, W. L. Granulomatous hypersensitivity. *Prog. Allergy* **11** (1967) 36-88.
- FERNANDEZ, J. M. M., CARBONI, E. A. and MERCAU, R. A. and SERIAL, A. Transformation of two borderline-lepromatous leprosy cases to tuberculoid, with healing. *Int. J. Lepr.* **30** (1962) 254-265.
- GAUGAS, J. M., REES, R. J. W., WEDDELL, A. G. M. and PALMER, E. Reversal effect of thymus grafts on lepromatous leprosy in thymectomized irradiated mice. *Int. J. Lepr.* **39** (1971) 388-395.
- GODAL, T., MYRVANG, B., SAMUEL, D. R., ROSS, W. F. and LØFGREN, M. Mechanisms of "reactions" in borderline tuberculoid (BT) leprosy. *Acta Pathol. Microbiol. Scand. [A] Suppl.* **236** (1973) 45-53.
- LAPORTE, R. Histologie des réactions locale d'hypersensibilité chez le cobaye (réactions allergiques à la tuberculine et réactions anaphylactiques). *Ann. Inst. Pasteur.* **53** (1934) 598-640.
- REES, R. J. W. and WEDDELL, A. G. M. Experimental models for studying leprosy. *Ann. N.Y. Acad. Sci.* **154** (1968) 214-236.
- RIDLEY, D. S. Reactions in leprosy. *Lepr. Rev.* **40** (1969) 77-81.
- RIDLEY, D. S. Hypersensitivity and immunity, reactions and classification. *Lepr. Rev.* **47** (1976) 171-174.
- ROSE, P. and MCDUGALL, C. Adverse reactions following pregnancy in patients with borderline (dimorphous) leprosy. *Lepr. Rev.* **46** (1975) 109-114.
- SOUZA CAMPOS, N. and SOUZA, P. R. Reactional states in leprosy. Leprosy reaction, tuberculoid reactivation (tuberculoid lepra reactions), reactional tuberculoid leprosy, borderline (limitantes lesions). *Int. J. Lepr.* **22** (1954) 259-272.
- DE SOUZA LIMA, L. The "pseudoexacerbation" reactional state of leprosy. *Int. J. Lepr.* **23** (1955) 429-434.
- TAJIRI, I. The "acute infiltration" reaction of lepromatous leprosy. *Int. J. Lepr.* **23** (1955) 370-384.
- TANAKA, A. and EMORI, K. Epithelioid cell granuloma formation by a synthetic bacterial cell wall component, muramyl dipeptide (MDF). *Amer. J. Path.* **98** (1980) 733-742.
- THOMAS, J., JOSEPH, M., RAMANUJAM, K., CRACKO, C. J. G. and JOB, C. K. The histology of the Mitsuda reaction and its significance. *Lepr. Rev.* **51** (1980) 329-339.

24. WADE, H. W. A tuberculoid-like reaction in lepromatous leprosy. *Int. J. Lepr.* **23** (1955) 443-446.
25. WADE, H. W. Effect of reactions in leprosy. *Int. J. Lepr.* **25** (1957) 399-400.
26. WATERS, M. F. R., LAING, A. B. G. and REES, R. J. W. Proven primary dapsone resistance in leprosy—a case report. *Lepr. Rev.* **49** (1978) 127-130.
27. WATERS, M. F. R., TURK, J. L. and WEMAMBU, S. N. C. Mechanisms of reactions in leprosy. *Int. J. Lepr.* **39** (1971) 417-428.