

Electrophysiologic and Histologic Studies in Leprosy and Some Acrodystrophic Neuropathies¹

S. S. Pandya and R. G. Chulawala²

The acrodystrophic neuropathies, of which leprosy is by far the most common, are a heterogeneous group of congenital and acquired disorders of the sensory pathway and in which acral (plantar and palmar) ulceration is a prominent clinical feature. Because of the superficial resemblance to the effects of leprosy neuropathy, it is not unusual for patients with such clinical features to be referred to a leprosy clinic. Although the neuropathologic and etiologic factors are varied, there is recognition that disturbed pain perception must play an important role in the pathogenesis of ulceration. As far as the peripheral sensory pathway is concerned, evidence based on electrophysiologic studies in man (⁶) and in animals (²) suggests that noxious stimuli are mediated by small myelinated and unmyelinated fibers in cutaneous nerves from non-hairy areas.

The study reported here attempts to provide information on the status of fiber groups in a cutaneous nerve in patients with leprosy and some other acrodystrophic neuropathies by recording the compound nerve action potential *in vitro*. Such techniques had earlier provided satisfactory correlation between electrical activity and neuropathologic status (⁶) in many types of peripheral neuropathy.

MATERIALS AND METHODS

Six patients presenting with plantar ulcers due to non-leprosy congenital and acquired neuropathies and six patients with leprosy neuropathy were the subjects of the study. Clinical and neurologic examination was carried out in each, paying particular

attention to the sensory status of the lower limbs. Sensory stimuli were provided by finger touch, pin-prick, and hot (90°C) and cold (ice) water. The results were expressed as severe loss (<50% correct responses to 50 stimuli), moderate loss (up to 75% correct responses), and not detectable (>90% correct responses).

A 7 cm long biopsy specimen of the sural nerve behind the ankle was obtained under light local anesthesia. In two patients a fascicular biopsy was taken in the manner described by other authors (5); in all the others the entire thickness of the nerve was excised. A 3.5 to 4 cm length of nerve was used for electrophysiologic studies. The piece was plunged into cold mammalian Tyrode's solution through which was bubbled a mixture of 95% oxygen and 5% CO₂ during transport to the neurophysiology laboratory (a distance of 3 miles). The nerve was cleaned under magnification and placed on a series of silver-silver chloride electrodes in a moist chamber aerated with 95% oxygen and 5% CO₂ at 37°C. After allowing the nerve sufficient time to reach ambient temperature, it was stimulated at one end and the compound action potentials recorded at a distance 15–20 mm away after crushing the segment between the two recording electrodes. Normal control nerves were obtained from four legs freshly amputated for sarcoma of the femur (through the courtesy of the surgeons of the Tata Memorial Hospital, Bombay).

The remainder of the biopsied nerve was used for histopathology, for fiber teasing, and for ultramicroscopy (the last not reported here).

Relevant clinical and pathologic data on each set of patients are given below:

Non-leprosy neuropathy patients. Patient 1 (S. F.) is a 14-year-old male with recurrent ulcerations of both great toes over a two year period. He has one 16-year-old sister who is similarly affected. On examination the cranial nerves and upper limbs were

¹ Received for publication on 26 September 1980; accepted for publication in revised form on 25 June 1981.

² S. S. Pandya, B.Sc., M.B.B.S., Research Officer; R. G. Chulawala, B.Sc., Acworth Leprosy Hospital, Society for Research, Rehabilitation and Education in Leprosy, Bombay 400 031, India.

normal. There was severe stocking anesthesia to all modalities. Tendon reflexes were absent. Investigations included EMG, which showed absent sural nerve action potentials bilaterally. The muscles were normal. X-rays of the lumbar spine were normal. Nerve biopsy showed chronic non-inflammatory fibrosing neuropathy with no myelin and almost no axons. No acid-fast bacilli were found. The diagnosis was congenital sensory neuropathy, possibly recessively inherited, Type II (?).

Patient 2 (M. G.) is an 18-year-old female with a non-healing ulcer of the right great toe of six months' duration. She had a history of acute backache, lower limb weakness, and transient urinary incontinence 6 years ago. Examination revealed the face and upper limbs to be normal. There was wasting and weakness in both legs and thighs and dense bilateral stocking anesthesia to all modalities. Investigations showed a normal spine X-ray and myelogram. The EMG showed denervation of lower limb muscles and absent right sural nerve action potential but a normal left sural nerve action potential. Nerve biopsy showed chronic non-inflammatory neuropathy with fibrosis and fiber degeneration in some funiculi, with normal findings in others. No acid-fast bacilli were seen. The diagnosis was cauda equina radiculoneuropathy of unknown cause.

Patient 3 (N. M. I.) is a 40-year-old female with absorption and repeated ulceration of the left great toe of two years' duration. There was no family history of similar illness. Examination showed the face and upper limbs to be normal. There was bilateral stocking anesthesia, more pronounced on the left than on the right, with loss of pain and temperature sense in the toes. Tendon reflexes were normal. Nerve biopsy showed non-inflammatory neuropathy with moderate myelin loss but good axon preservation. No acid-fast bacilli were seen. The diagnosis was sensory neuropathy of unknown cause.

Patient 4 (A. F.) is a 17-year-old female who is the sister of case 5. She has repeated cornification and ulceration under both great toes of 5 years' duration. Examination showed the face and upper limbs to be normal. There was minimal sensory loss in the feet, most marked around the ulcers.

The muscles and deep tendon reflexes were normal. EMG studies showed the muscles to be normal. The right and left sural nerve action potentials were normal. Nerve biopsy showed non-inflammatory fibrosing neuropathy with moderate myelin loss but good axon preservation. No acid-fast bacilli were seen and no amyloid was identified. The diagnosis was congenital sensory neuropathy, possibly recessively inherited, Type I (?).

Patient 5 (M. F.) is a 23-year-old male who is the brother of case 4. He had repeated ulceration of the soles of 10 years' duration. There was occasional cornification and infection of the fingertips. Examination showed the face and trunk to be normal. Two-point discrimination and pain-temperature perception were impaired in the fingertips. There was bilateral stocking anesthesia, more pronounced distally than proximally, to all modalities. The ankle reflexes were absent. An EMG at age 16 showed no significant abnormality. A repeat study at the age of 23 showed normal muscles. Sural nerve action potentials showed reduced amplitude. Nerve biopsy showed chronic noninflammatory fibrosing neuropathy with moderate myelin and axon loss. The diagnosis was congenital sensory neuropathy, Type I (?).

Patient 6 (M. L. P.) is a 55-year-old male. He had a history of severe paresthesias of the lower limbs of 1 year duration. He had recurrent painless plantar ulceration on the right side of 6 months' duration. He was a chronic alcoholic. Examination showed the face and upper limbs to be normal. There was severe bilateral stocking anesthesia to all modalities. The ankle reflexes were absent. EMG studies showed denervation in foot muscles. The sural and median nerve action potentials showed reduced amplitude. A nerve biopsy showed non-inflammatory fibrosing neuropathy with demyelination and axonal degeneration. The diagnosis was alcoholic neuropathy.

Leptous neuropathy patients. Patient 1 (M. P.) is a 32-year-old male. He had progressive numbness of the left leg and foot of 8 years' duration. There were no skin lesions. The left sural nerve was enlarged. There was severe anesthesia to all modalities in the left leg and foot. No motor deficit was found. He was felt clinically to have

BT leprosy. A skin biopsy showed no evidence of leprosy. A sural nerve biopsy showed chronic inflammatory (mostly lymphocytic) fibrosing neuropathy. There was marked myelin/axon degeneration. A few acid-fast bacilli were identified. The diagnosis was polyneuritic borderline leprosy with questionable downgrading.

Patient 2 (R. N. S.) is a 55-year-old male. He has had a history of anesthesia involving the left ankle of two years' duration. More recently it has involved the right ankle. Examination showed no skin lesions, dryness of feet, weakness of the left foot, severe sensory loss to all modalities involving the left foot, and no enlarged nerves. He was felt clinically to have borderline leprosy. Sural nerve biopsy showed a dense granulomatous infiltrate of lymphocytes and macrophages with vasculitis and endo- and perineurial fibrosis. There was myelin/axon degeneration. There were moderate numbers of acid-fast bacilli identified. The diagnosis was polyneuritic borderline leprosy with downgrading.

Patient 3 (M. R.) is an 18-year-old male. He had a history of anesthesia of the right foot since childhood and developed foot drop in the last two years. Examination showed many erythematous large and small anesthetic lesions on the skin. The sural and peroneal nerves were enlarged. He was felt clinically to have BT leprosy. Sural nerve biopsy showed complete replacement of some funiculi by tuberculoid granulomatous infiltrates. There was some fibrosis. A few funiculi were almost normal. A few acid-fast bacilli were identified. The final diagnosis was borderline tuberculoid leprosy.

Patient 4 (A. U. S.) is a 25-year-old female. She had multiple hypopigmented macules, erythema, and swelling of the face and limbs which developed following a miscarriage 6 months prior to the study. Examination showed moderate to severe anesthesia in both feet, more pronounced distally than proximally. The peripheral nerves were not significantly enlarged. She was felt clinically to have BL type leprosy. Sural nerve biopsy showed a lymphocytic/macrophage infiltrate in all funiculi with endoneurial fibrosis and edema. There was

moderate fiber degeneration and moderate numbers of acid-fast bacilli demonstrated. The final diagnosis was lepromatous leprosy.

Patient 5 (K. S.) is a 40-year-old male who had a history of dense anesthesia involving both feet for many years. Examination showed many hypopigmented and erythematous hypoesthetic and anesthetic lesions. The sural nerves were enlarged. He was felt clinically to have BT/BB leprosy. Sural nerve biopsy showed chronic small cell infiltration and dense funicular and extra funicular fibrosis. No normal nerve fibers were seen. A few acid-fast bacilli were demonstrated. The final diagnosis was chronic borderline leprosy.

Patient 6 (P. A. A.) is a 20-year-old male who had generalized erythema and swelling of the hands and feet of unknown duration. Examination showed the features of diffuse lepromatous leprosy. There was moderate anesthesia in the distal legs and feet. He was felt clinically to have lepromatous leprosy. Sural nerve biopsy showed marked endoneurial edema and fibrosis. There was a small amount of mononuclear infiltrate in the endo- and perineurium. There was moderate fiber damage. A few acid-fast bacilli were seen. The final diagnosis was lepromatous leprosy.

RESULTS

The compound action potentials recorded from the 12 experimental sural nerves are illustrated in Figs. 1 and 2. A normal nerve action potential is also shown (Fig. 2, bottom) and brings out clearly the three main peaks which are characteristic of the activity in the fast-conducting large myelinated fibers, the slower conducting small myelinated fibers, and the very slow conducting unmyelinated fibers respectively. The three peaks are conventionally labelled as A alpha, A delta, and C; they are distinguished from each other not only by their speeds of conduction (i.e., the latency), but by their relative amplitudes (which roughly correlates with the fiber density in the nerve). The status of the myelinated fibers was inferred from the electrophysiologic data, that of the unmyelinated fibers from the electrical findings alone.

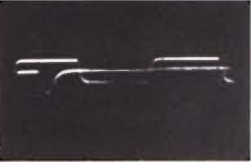
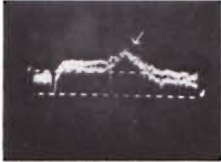


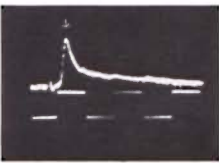
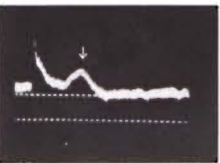
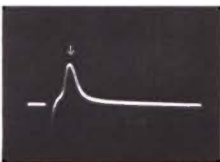


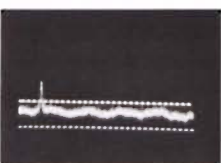

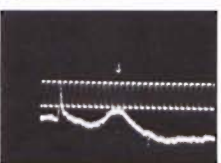

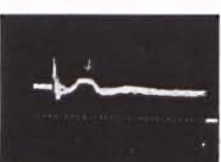
Patient no.	Patient's initials	Diagnosis	Myelinated fibers: A alpha and A delta	Unmyelinated fibers C peak	Remarks
1	S. F.	Congenital sensory neuropathy; Type II			Absent A peaks; C peak present
			Fig. 1a(i). 10 μ v, 1 ms	Fig. 1a(ii). 10 μ v, 1 ms	
2	M. G.	Cauda equina radiculo- neuropathy; ? cause			Single, small A peak; C peak present
			Fig. 1b(i). 10 μ v, 1 ms	Fig. 1b(ii). 20 μ v, 1 ms	
3	N. M. I.	Sensory neuropathy; ? cause			Single, small A peak; C peak present
			Fig. 1c(i). 20 μ v, 1 ms	Fig. 1c(ii). 10 μ v, 1 ms	
4	A. F.	Congenital sensory neuropathy; Type I			Single, small A peak; C peak present
			Fig. 1d(i). 200 μ v, 1 ms	Fig. 1d(ii). 20 μ v, 1 ms	
5	M. F.	Congenital sensory neuropathy; Type I			Single, small A peak; C peak absent
			Fig. 1e(i). 10 μ v, 1 ms	Fig. 1e(ii). 10 μ v, 1 ms	
6	M. L. P.	Alcoholic neuropathy			Small, single A peak; C peak present
			Figure 1f(i). 50 μ v, 1 ms	Fig. 1f(ii). 20 μ v, 1 ms	
7	—	Normal			A alpha A delta; 2 C peaks present
			Fig. 1g(i). 1000 μ v, 1 ms	Fig. 1g(ii). 100 μ v, 1 ms	

FIG. 1. Sural nerve compound action potentials in non-leprous neuropathes (a-f), and in a control normal nerve (g).





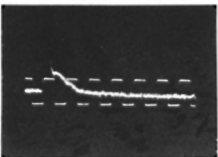
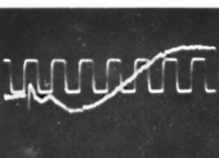
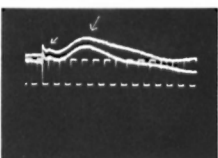
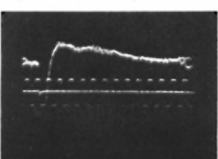
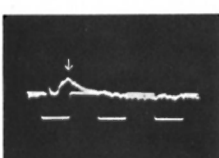
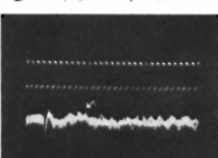
Patient no.	Patient's initials	Diagnosis	Myelinated fibers A alpha and A delta	Unmyelinated fibers C peak	Remarks
1	M. P.	Polyneuritic borderline leprosy			Single, tiny, myelinated fiber peak; C absent
			Fig. 2a(i). 10 μ v, 1 ms		
2	R. N. S.	Downgrading borderline polyneuritic leprosy			Small, myelinated fiber peaks C absent
			Fig. 2b(i). 200 μ v, 1 ms	Fig. 2b(ii). 10 μ v, 1 ms	
3	M. R.	Borderline tuberculoid leprosy			Single, small A peak; no C peak
			Fig. 2c(i). 50 μ v, 1 ms	Fig. 2c(ii). 10 μ v, 1 ms	
4	A. U. S.	Lepromatous leprosy			Single, small A peak; C peak present
			Fig. 2d(i). 10 μ v, 1 ms	Fig. 2d(ii). 10 μ v, 1 ms	
5	K. S.	Chronic borderline leprosy			No A or C peaks
				Fig. 2e(ii). 10 μ v, 1 ms	
6	P. A. A.	Lepromatous leprosy			Single, small A peak; small C peak
			Fig. 2f(i). 10 μ v, 1 ms	Fig. 2f(ii). 10 μ v, 1 ms	

FIG. 2. Sural nerve compound action potentials in leprous neuropathy.

DISCUSSION

Patients with peripheral neuropathy usually have one of three types of sensory loss⁽⁶⁾. In the first type there is the predominant loss of touch, vibration, and joint position sense without loss of pain-temperature sen-

sation. In the second type there is loss of pain-temperature sensation with preservation of touch-pressure, etc.; in the third type of peripheral neuropathy all modalities may be affected. A glance at the clinical and electrophysiologic data presented here

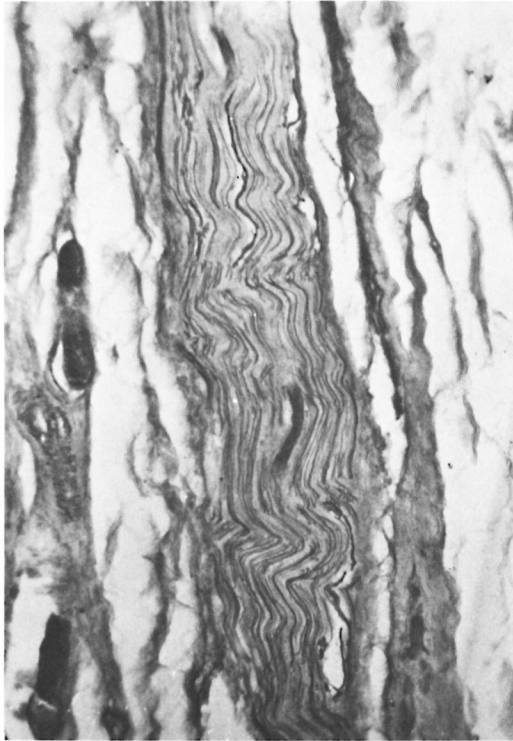

FIG. 3. (Non-leprosy neuropathy case 6). Alcoholic neuropathy longitudinal section of sural nerve showing a fair preservation of axons (although many were demyelinated) and endoneurial fibrosis (Holmes Silver stain $\times 60$).

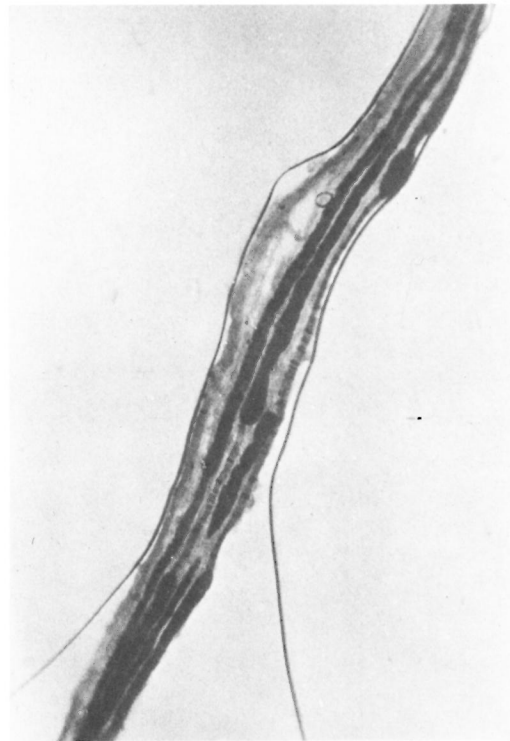


FIG. 4. (Leprous neuropathy case 1). Four teased fibers from sural nerve showing from left to right, complete demyelination, irregularity of the myelin sheath at the internode, a short demyelinated segment, and a longer, thinly myelinated segment with a bulbous thickening of myelin in the adjacent internode (Osmic acid $\times 150$).

shows that all had the third or combined type of sensory deficit. Although in leprosy neuropathy in its early stages (as also in early skin lesions) it is easy to demonstrate pain-temperature disturbances, there is no histologic (^{3,8,9}) or electrophysiologic evidence (¹) to suggest that myelinated fibers are relatively immune from attack.

The compound action potentials from the non-leprosy and leprosy nerves (Figs. 1 and 2) revealed certain similarities and contrasts:

a) All three major peaks (A alpha, A delta, and C) were abnormal in amplitude in both groups.

b) Absence of the C peak due to unmyelinated axons was a conspicuous feature of the leprosy nerve action potentials; by contrast, the C peak was present in nearly all non-leprosy nerve action potentials.

c) The myelinated fiber peak was frequently seen as single, since there was no

significant difference between conduction times in the larger and smaller myelinated axons. This could be a reflection of an attenuation in fiber diameter and reduction in inter-nodal length which result from degenerative-regenerative activity in the nerve (⁴).

d) Within the leprosy group the pattern of electrical abnormality bore no relationship to the type of leprosy, only to the extent and severity of axon damage. This is understandable because the functional status of a nerve at a given moment is the sum total of the vicissitudes through which it has passed; this is particularly so in the long years of development of borderline and lepromatous leprosy.

Histologic examination showed that endoneurial fibrosis was present to a greater (in the leprosy nerves) or lesser (in the non-leprosy nerves) extent in all specimens. Myelin loss or degeneration outweighed ax-



FIG. 5. (Leprous neuropathy case 6). Longitudinal section of sural nerve in lepromatous leprosy showing endoneurial fibrosis, endoneurial edema leading to fiber separation, and an inflammatory exudate (Holmes silver stain $\times 150$).

onal pathology in alcoholic neuropathy (Fig. 3). The nerves from patients with hereditary neuropathy fell into two main groups—Type I showing some preservation of myelinated fibers and Type II showing no myelinated axons or action potentials but a retained C fiber peak (⁷). Teased fiber preparations of these nerves stained with osmic acid showed that when myelinated axons were seen, they were apparently normal. Demyelination-degeneration-regeneration was a feature of leprosy and alcoholic neuropathy (Fig. 4). In addition, leprosy nerves showed endoneurial edema (Fig. 5), perineurial fibrosis, and inflammation, which would be expected to contribute to nerve fiber damage.

We believe that myelinated fiber (large diameter) damage, which is shown to be an integral feature of the cases studied here, possibly contributed not only to disturbed touch-pressure sensation but aggravated in-

accuracies of pain-temperature perception by the patient. It is interesting that even in primary amyloidosis, an archetypal small fiber neuropathy, touch-pressure abnormalities are constantly seen (⁶). We speculate that there is a role for them in the pathogenesis of plantar ulceration.

SUMMARY

In vitro electrophysiologic and light microscopic studies were carried out on the sural nerve in six patients with non-leprosy neuropathy with plantar ulceration and in six patients with various types of leprosy neuropathy. In the non-leprosy group (with congenital and acquired neuropathy) the abnormalities in the compound action potentials of the myelinated (large and small) fibers were usually more striking than those in the unmyelinated fibers potentials. In the leprosy neuropathies, on the other hand, the three major fiber groups tended to be involved indiscriminately, the unmyelinated fiber potential being as liable to abnormality as the myelinated fiber potentials. Histologically the nerve fiber damage in the congenital neuropathies appeared to be moderate to gross involvement of the myelinated fibers without the prominent demyelination and degeneration/regeneration seen in leprosy and the other acquired neuropathies. Leprous neuropathy showed, besides fiber abnormalities, the simultaneous deleterious effects of inflammation and fibrosis.

It is a matter for speculation whether disturbed conduction in the large myelinated touch-pressure mediating fibers contributes significantly to impaired pain perception (mediated by small fibers) and plantar ulceration in leprosy and other acrodystrophic neuropathies.

RESUMEN

Se hicieron estudios electrofisiológicos *in vitro* y observaciones al microscopio de luz, en los nervios surales de seis pacientes con neuropatía no leprosa con ulceración plantar, y en seis pacientes con diversos tipos de neuropatía leprosa. En el grupo no leproso (con neuropatías congénitas o adquiridas), las anomalías en los potenciales de acción de las fibras mielinizadas (grandes y pequeñas) fueron más marcadas que las anomalías en los potenciales de las fibras no mielinizadas. En las neuropatías leprosas, por otro lado, los tres grupos mayores de fibras estu-

vieron afectados de manera indiscriminada, siendo los potenciales de las fibras no mielinizadas tan susceptibles a la anomalía como los potenciales de las fibras mielinizadas. Histológicamente, el daño a la fibra nerviosa en las neuropatías congénitas osciló de moderada a profunda afección de las fibras mielinizadas sin la desmielinización prominente y la degeneración/regeneración observada en lepra o en otras neuropatías adquiridas. La neuropatía leprosa mostró, además de las anomalías en las fibras, los efectos deletéreos simultáneos de la inflamación y fibrosis.

Se especula si la afectada conducción en las grandes fibras mielinizadas responsables de la sensación "toque-presión" contribuye de manera importante a la disminuida percepción al dolor (mediada por las fibras pequeñas) y a la ulceración plantar en lepra y en otras neuropatías acrodistróficas.

RÉSUMÉ

Chez 6 malades atteints de neuropathie d'origine non lépreuse, accompagnée d'ulcération plantaire, et chez six malades souffrant de divers types de neuropathie d'origine lépreuse, on a procédé à des études électrophysiologique *in vitro*, et à des études pratiquées au microscope optique, sur le nerf crural. Dans le groupe de malades ne souffrant pas de lèpre, et présentant des neuropathies congénitales ou acquises, les anomalies notées dans les potentiels d'action composés des fibres myélinisées, tant de petites que de grandes dimensions, étaient généralement beaucoup plus marquées que les anomalies présentées par les potentiels des fibres myélinisées. Sur le plan histologique, l'endommagement de la fibre nerveuse dans les neuropathies congénitales varie depuis un degré modéré jusqu'à une atteinte importante des fibres myélinisées, sans que ceci soit accompagné de démyélinisation marquée ou d'un processus de dégénérescence/régénération tels qu'on les voit dans la lèpre et dans d'autres neuropathies acquises. La neuropathie d'origine lépreuse montrait, outre des anomalies au niveau des fibres, des effets destructeurs simultanés de l'inflammation et de la fibrose.

On peut spéculer pour savoir si les troubles de la conduction des fibres myélinisées épaisses qui transmettent la sensibilité à la pression et au toucher, contribuent significativement ou non à la diminution de la perception de la douleur, qui est pour sa part transmise par les fibres minces, ainsi qu'aux ulcérations plantaires dans la lèpre et dans d'autres neuropathies acrodystrophiques.

Acknowledgments. The study was supported by a grant-in-aid from the Bombay Hospital Trust. The electrophysiologic studies were conducted at the Bombay Hospital. Thanks are due to the Superintendent of the Acworth Leprosy Hospital and the President of the A.L.H. Society for Research, Rehabilitation and Education in Leprosy for permission to conduct the study.

REFERENCES

1. ANTIA, N. H., PANDYA, S. S. and DASTUR, D. K. Nerves in the arm in leprosy. 1. Clinical, operative and electrodiagnostic aspects. *Int. J. Lepr.* **38** (1970) 12-29.
2. BESSOU, P. and PERL, E. R. Responses of cutaneous sensory units with unmyelinated fibers to noxious stimuli. *J. Neurophysiol.* **32** (1969) 1025-1043.
3. DASTUR, D. K. Cutaneous nerves in leprosy: the relationship between histopathology and cutaneous sensibility. *Brain* **78** (1955) 615-633.
4. DASTUR, D. K., PANDYA, S. S. and ANTIA, N. H. Nerves in the arm in leprosy. 2. Pathology, pathogenesis, and clinical correlations. *Int. J. Lepr.* **38** (1970) 30-48.
5. DYCK, P. J. and LOFGREN, E. P. Method of fascicular biopsy of human peripheral nerve for electrophysiologic and histologic study. *Mayo Clin. Proc.* **41** (1966) 778-784.
6. DYCK, P. J., LAMBERT, E. H. and NICHOLS, P. C. Quantitative measurements of sensation related to compound action potential and number and sizes of myelinated and unmyelinated fibers of sural nerve in health, Friedreich's Ataxia, hereditary sensory neuropathy and tabes dorsalis. *Handbook of EEG and Clin. Neurophysiol.* **9** (1971) 83-118.
7. DYCK, P. J. and OHTA, M. Neuronal atrophy and degeneration predominantly affecting peripheral sensory neurons. In: *Peripheral Neuropathy*. Dyck, P. J., Thomas, P. K. and Lambert, E. H., eds. Philadelphia: W. B. Saunders Co., 1975.
8. FINLAYSON, M. H., BILBAO, J. H. and LOUGH, J. O. The pathogenesis of the neuropathy in dimorphic leprosy: electromicroscopic and cytochemical studies. *J. Neurol.* **33** (1974) 446-455.
9. JOB, C. K. Pathology of the peripheral nerve lesions in lepromatous leprosy. *Int. J. Lepr.* **39** (1971) 251-268.