

CORRESPONDENCE

This department is for the publication of informal communications that are of interest because they are informative and stimulating, and for the discussion of controversial matters. The mandate of this JOURNAL is to disseminate information relating to leprosy in particular and also other mycobacterial diseases. Dissident comment or interpretation on published research is of course valid, but personality attacks on individuals would seem unnecessary. Political comments, valid or not, also are unwelcome. They might result in interference with the distribution of the JOURNAL and thus interfere with its prime purpose.

In Situ Characterization of T Lymphocyte Subsets in Leprosy Granulomas

TO THE EDITOR:

The host response in leprosy is probably determined by mechanisms of cell-mediated immunity. To further evaluate the role of T lymphocyte subsets in the host response, we used monoclonal antibodies and an immunoperoxidase technique to study *in situ* frozen sections of leprosy skin lesions. We wish to report results of our investigations into the immunohistologic architecture of leprosy granulomas.

Fourteen patients were classified according to the criteria of Ridley (¹). Four were determined to be tuberculoid (TT/BT); 2 were borderline (BB) in reversal reaction; 1 was borderline lepromatous (BL); and 7 were lepromatous (LL), 5 of whom had ENL. Six patients were treated, but the results in these cases did not differ from those in the untreated patients.

In brief, tissues were placed in OCT media and snap frozen in liquid nitrogen. Antigens were detected by a modified immunoperoxidase method (^{2,3}). Five micron sections were fixed for 10 min in cold acetone after which the following reagents were sequentially applied with washes in phosphate buffered saline between incubations:

- 1) primary mouse anti-human monoclonal antibody (10 µg/ml) directed against a pan T cell marker (Leu 1, Becton Dickinson), against a T suppressor/cytotoxic marker (Leu 2 or OKT 8, Ortho), or against T helper/inducer marker (Leu 3, Becton Dickinson)

- 2) biotinylated horse anti-mouse serum (Vector)
- 3) biotin-avidin-horseradish peroxidase conjugate (Vector)
- 4) diaminobenzidine, a chromogenic substrate with hydrogen peroxide
- 5) cupric sulfate for darkening the reaction product.

Slides were then counterstained with hematoxylin if desired, dehydrated, and mounted in Permount.

Two immunohistologic patterns were observed. In the four tuberculoid tissues, lymphocytes bearing the pan T cell antigen were present throughout the granuloma mantle and also within the epithelioid cell aggregates. However, T suppressor/cytotoxic and T helper/inducer cells were found to occupy different locations in the granuloma. Lymphocytes expressing the T suppressor/cytotoxic phenotypes were predominantly in the mantle (Fig. 1); while lymphocytes staining for the T helper/inducer antigen were found distributed throughout the granuloma (Fig. 2).

In the ten non-tuberculoid tissues, lymphocytes bearing the pan T cell antigen were observed in the granulomas, but no mantle of suppressor/cytotoxic T lymphocytes was observed. Instead helper/inducer and suppressor/cytotoxic phenotypes were admixed throughout the granuloma among the histiocytes.

The intimate contact of T helper cells with epithelioid cells in tuberculoid granulomas

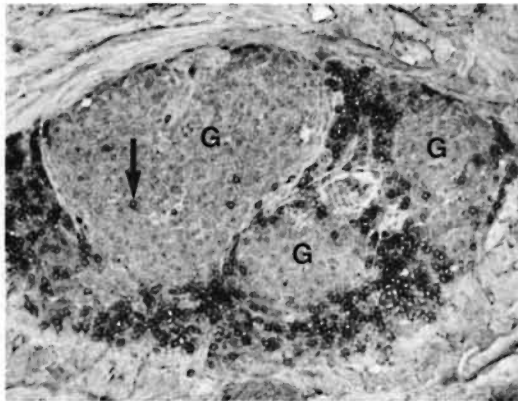


FIG. 1. One large and two small tuberculoid granulomas (G). Cells staining positively for suppressor/cytotoxic phenotype are seen as small dark rings. These positive cells are predominantly at periphery of the granulomas, but a few are located centrally (arrow). (Frozen section, OKT 8 counterstained with hematoxylin, $\times 150$.)

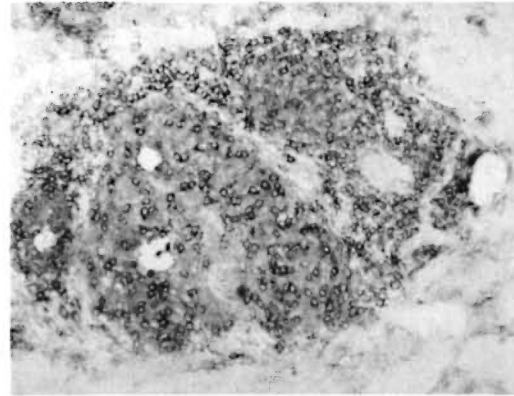


FIG. 2. Same aggregate of three granulomas as in Figure 1. Cells bearing helper/inducer phenotype, small dark rings, are distributed throughout the granuloma and show no predilection for peripheral mantle. (Frozen section, Leu 3 with no counterstain, $\times 150$.)

may reflect the active cooperation of these diverse cell types in promoting an effective immune response. The suppressor T cells at the periphery of these granulomas may contribute to the confinement of bacilli within circumscribed granulomas.

The lepromatous and reversal reaction tissues did not show this architectural separation of T lymphocyte subsets. Instead, the relatively haphazard arrangement of helper and suppressor cells might reflect the lack of an organized immune response, so permitting florid bacillary proliferation.

The functional consequences of these differing immunohistologic patterns are at present still speculative. However, it is of considerable interest that two patterns have been identified, conforming to two major histologic patterns and to two radically different immune states. As other cell surface antigens are recognized and other segments of the leprosy spectrum become available for study, it might be expected that new

data will enhance our understanding of the tissue response in leprosy.

—Robert L. Modlin, M.D.
—Florence M. Hofman, Ph.D.
—Clive R. Taylor, M.D., D. Phil.
—Thomas H. Rea, M.D.

*Departments of Dermatology and
Pathology
Los Angeles County/University of
Southern California Medical Center
2025 Zonal Avenue
Los Angeles, CA 90033 U.S.A.*

REFERENCES

1. RIDLEY, D. S. Histological classification and the immunological spectrum of leprosy. *Bull. WHO* **51** (1974) 451–465.
2. TAYLOR, C. R. Immunoperoxidase techniques: Practical and theoretical aspects. *Arch. Pathol. Lab. Med.* **102** (1978) 113–121.
3. HSU, S.-M., RAINE, L. and FANGER, H. Use of avidin-biotin-peroxidase complex (ABC) in immunoperoxidase techniques: A comparison between ABC and unlabeled antibody (PAP) procedures. *J. Histochem. Cytochem.* **29** (1981) 577–580.