

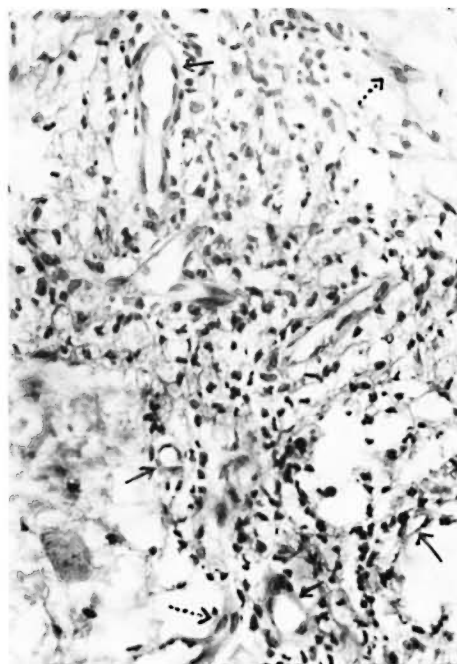
Oral Zinc in the Trophic Ulcers of Leprosy

TO THE EDITOR:

We would like to draw attention to oral zinc sulfate in the healing of uncomplicated trophic ulcers in leprosy. Zinc sulfate has been tried locally as well as orally and has been found effective in healing in cases of chronic venous leg ulcerations (^{3, 5}), incised wounds (⁶), sickle cell ulcers (⁷), skin breakdown in kwashiorkor (²), bed sores (¹), and experimentally induced burn wounds in rats (⁴). Recently Söderberg, *et al.* (⁸) have shown faster healing of uncomplicated ulcers of leprosy with local zinc tape application. Until now there have been no reports on the effect of oral zinc sulfate on granulation tissue or on trophic ulcers of leprosy. The present communication deals with the effect of oral zinc sulfate in uncomplicated trophic ulcers of leprosy.

Twenty-five patients (13 LL, 8 BL, 4 BT) were selected randomly at the leprosy clinic of the S.M.S. Medical Hospital, Jaipur, India. Twenty were males and five were females. Their ages ranged from 20–60 years. Trophic ulcers were present on the plantar surfaces of their feet, particularly on the soles and the heads of the metatarsal bones. These were about 2 cm–4 cm in diameter, round or oval in shape, and were about 1 cm–2 cm deep. There was no involvement of bones. Secondary infection was present in ten patients. The duration of the ulcers ranged from 2–6 months. Serum zinc levels were estimated in 18 cases before starting zinc therapy and were found to be low (mean \pm S.D. = $75 \pm 8.5 \mu\text{g}/100 \text{ ml}$, range 70–90 $\mu\text{g}/100 \text{ ml}$).

All patients were given 220 mg zinc sulfate/day orally in addition to specific anti-leprosy drugs. In 13 cases, zinc was given for three months and in 12 cases, for 18 months since they were taking zinc for immunostimulation also. Cotrimoxazole was given to patients with secondary infection. Locally the wounds were cleaned with saline solution twice a day and dressed with dry gauze. The patients were not provided with



THE FIGURE. Dermal neovascularization (\uparrow) and endothelial cell proliferation (\uparrow) after zinc therapy. (H&E $\times 600$).

any special footwear and were not admitted to the hospital, but were trained to clean and dress the ulcers themselves at home. None of the patients was immobilized. Skin biopsies were taken from lesions away from the ulcer (the thigh in 15 cases and the back in ten cases) before and after three months of therapy.

In most of the patients the ulcers became clean and healthy in about two weeks. Healthy granulation tissue and re-epithelialization became obvious in the third week and complete healing took place within 6–12 weeks, depending on the size and depth of the ulcers. No recurrence was seen after up to 12–18 months of follow up. One remarkable observation in the skin biopsies after zinc therapy was neovascularization and endothelial cell proliferation in the der-

mis (The Figure). We have consistently observed this phenomenon of neovascularization in patients who are taking zinc for immunostimulation.

Our observations suggest that zinc sulfate might be helping in the formation of healthy granulation tissue by means of neovascularization and endothelial cell proliferation in addition to wound débridement and epithelialization. Further trials are in progress.

—N. K. Mathur, M.D., F.C.A.I.

Professor and Head

—R. A. Bumb, M.B.B.S.

Senior Resident

Department of Dermatology

S.M.S. Medical Hospital

Jaipur, India

REFERENCES

1. COHEN, C. Zinc in bed sores. *Br. Med. J.* **2** (1968) 567.
2. GOLDEN, M. H. N., GOLDEN, B. E. and JACKSON, A. A. Skin breakdown in kwashiorkor responds to zinc. *Lancet* **1** (1980) 1256.
3. HALLBOOK, T. and LANNER, E. Serum zinc and healing of venous leg ulcers. *Lancet* **2** (1971) 780–782.
4. HALLMANS, G. Healing of experimentally induced burn wounds. *Scand. J. Plast. Reconstr. Surg.* **12** (1978) 105–109.
5. HUSSAIN, S. L. Oral zincsulfate in leg ulcers. *Lancet* **1** (1969) 1069–1071.
6. PORIES, W. J., HENZEL, J. H., ROB, C. G. and STRAIN, W. H. Acceleration of wound healing in men with zinc sulfate given by mouth. *Lancet* **2** (1967) 121–124.
7. SERJEANT, G. R., GALLOWAY, R. E. and GUERI, M. C. Oral zinc sulfate in sickle cell ulcers. *Lancet* **2** (1970) 891–892.
8. SÖDERBERG, T., HALLMANS, G., STENSTRÖM, S., LOBO, D., PINTO, J., MAROOF, S. and VELLUT, C. Treatment of leprosy wounds with adhesive zinc tap. *Lepr. Rev.* **53** (1982) 271–276.