

## CORRESPONDENCE

*This department is for the publication of informal communications that are of interest because they are informative and stimulating, and for the discussion of controversial matters. The mandate of this JOURNAL is to disseminate information relating to leprosy in particular and also other mycobacterial diseases. Dissident comment or interpretation on published research is of course valid, but personality attacks on individuals would seem unnecessary. Political comments, valid or not, also are unwelcome. They might result in interference with the distribution of the JOURNAL and thus interfere with its prime purpose.*

Multiple Axonal Myelination in the Experimental  
Mouse Leprosy Model

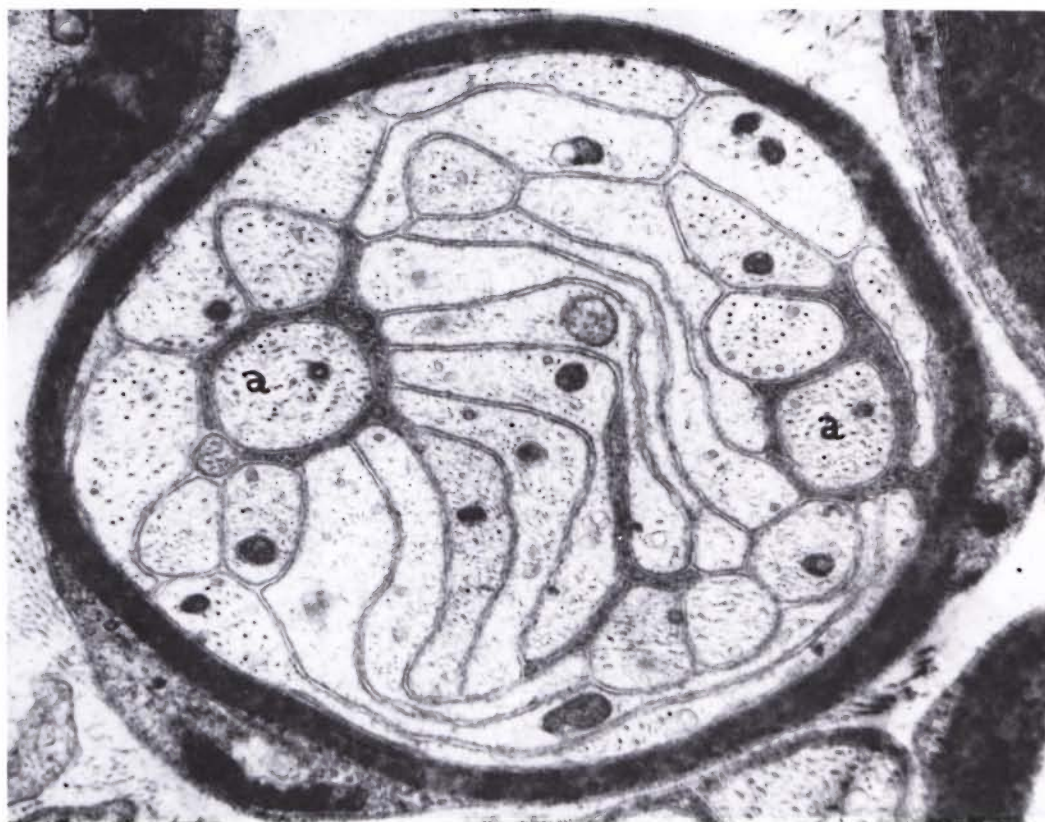
## TO THE EDITOR:

Myelination around multiple axons is reportedly a rare phenomenon in mature peripheral nerves. Brown and Radich (1) observed a six-times higher incidence of multiple axonal myelination in developing sciatic nerves of mice with benign muscular dystrophy as compared to normal mice. They speculated that the multiple axonal myelination could result from either an axonal-Schwann cell abnormality or it may be the nonspecific response of the uncommitted Schwann cell to an early failure of myelination. They also presumed that such structures are unstable and that they ultimately degenerate. A high incidence of multiple axonal myelination was observed in an experiment carried out to study the effect of *Mycobacterium leprae* infection followed by dapsone (DDS) treatment. An attempt is made to understand and postulate the formation of such fibers.

Ten non-immunosuppressed Swiss white female mice, aged six weeks, were inoculated into the right hind foot pad with 5000 *M. leprae* obtained from a patient who had shown clinical evidence of resistance to DDS therapy. A second batch of ten mice were inoculated similarly, and were given oral DDS in a dose of 50 µg/day from day zero. The third batch of ten mice were given only oral DDS 50 µg/day/mouse. Sciatic nerve biopsies were obtained from three mice from each batch at the sixth post-inoculation month. Nerves were fixed *in situ* with 2.5% glutaraldehyde, further fixed in cacodylate-buffered 2.5% glutaraldehyde, and post-fixed in buffered 1% OsO<sub>4</sub>, dehydrated and embedded in epoxy resin mixture. Foot pad harvest was also done simultaneously of the individual mice. The results were compared with six normal nerves obtained from uninoculated control mice of the same age group maintained under similar conditions.

THE TABLE. *Sciatic nerves of mice showing number of fibers with multiple axonal myelination.*

Experimental detail	Sciatic nerves					
	Mouse 1		Mouse 2		Mouse 3	
	Right	Left	Right	Left	Right	Left
Mice with 5000 <i>M. leprae</i> inoculated into the right foot pad only	Nil	1	1	2	1	1
Mice with 5000 <i>M. leprae</i> inoculated into the right foot pad + oral DDS 50 µg/day	16	19	15	22	6	8
Mice with only oral DDS 50 µg/day	Nil	1	Nil	Nil	2	Nil
Uninoculated normal mice	2	1	Nil	Nil	1	Nil



THE FIGURE. Transverse section of sciatic nerve of Mouse 2 inoculated in the foot pad with *Mycobacterium leprae* and given oral DDS in a dose of 50  $\mu\text{g}/\text{day}$ . Biopsy at the sixth post-inoculation month shows a large cluster of axons surrounded by a myelin ring system. Most of the axons are tangentially arranged and have watery axoplasm. Few axons (a) cut in transverse plane are individually ensheathed by Schwann cell processes ( $\times 18,125$ ).

No growth of *M. leprae* was recorded at the sixth post-inoculation month in the foot pad harvests from any of the mice treated with DDS 50  $\mu\text{g}/\text{day}$ ; whereas the untreated mice showed a tenfold increase in the bacillary growth. However, *M. leprae* from the same patient revealed partial resistance to DDS, i.e., a concentration of 5  $\mu\text{g}/\text{day}$  showed bacillary growth in the foot pads but here the nerves were not studied.

All of the six nerves from the mice with *M. leprae* infection treated with oral DDS 50  $\mu\text{g}/\text{day}$  showed a high incidence of fibers with myelination around multiple axons. The Table shows the number of such fibers encountered in individual nerves in each group of mice, i.e., with *M. leprae* infection, with *M. leprae* followed by DDS treatment, DDS alone, and the uninoculated normal controls.

The count was carried out on ultrathin transverse sections scanned under the Philips 300 microscope. Sections were mounted on 50 micron TAAB lab grids, where 20–25 grid squares covered the whole funicle of the sciatic nerve.

A careful study of both transverse and longitudinal serial sections of these fibers with myelination around multiple axons revealed abnormalities such as swelling of the axons, watery appearance of the axoplasm, tangential arrangement of the axons and the presence of some unusually small axons. The axons within the myelin ring system often did not have individual Schwannian ensheathment (The Figure). The longitudinal sections of these fibers clearly demonstrated that these multiple axonal myelinizations occurred within a short segment of an otherwise unmyelinated group of fibers.

An average of 14 fibers per funicle with multiple axonal myelination, observed in the mice with *M. leprae* infection followed by DDS treatment, was striking as compared to nerves of mice with only *M. leprae*, only DDS, and normal, age-matched controls kept under similar conditions. Although the exact cause for such abnormal myelination is not very clear, we can speculate that the unmyelinated fibers and their Schwann cells, which are known to be affected following *M. leprae* infection (<sup>4</sup>), have shown abnormal regenerative activity following DDS treatment.

Abnormalities such as a) swelling of the axons, b) tangential arrangement of the axons, c) the presence of miniature axons as well as d) partial or total loss of individual ensheathment by the Schwannian processes of the axons within the myelin ring system suggest that the myelination had commenced following partial disorganization of a parent unmyelinated fiber unit.

There is no definitive evidence, such as degenerating myelinated fibers or myelin debris, to suggest that there was prior axonal degeneration of myelinated fibers. It is therefore unlikely that multiple axonal myelination is a regenerative activity following axonal degeneration. Waxman (<sup>5</sup>) suggests that the branching of a single axon within its myelin sheath would result in myelination of multiple axons. On the other hand, Brown and Radich (<sup>1</sup>) have shown a number of axons lying outside the myelin ring system. They propose that the multiple axonal myelination is a focal phenomenon occurring within one internodal length of myelin along the course of an otherwise unmyelinated bundle of axons. This is also the opinion of Okada, *et al.* (<sup>2</sup>). Our own observations favor the proposition by Brown and Radich (<sup>1</sup>).

Our material does not give any evidence to suggest that such fibers degenerate in the course of time. In this mouse leprosy we have a unique experimental model of selective involvement of unmyelinated axons and their Schwann cells in the initial stages of infection. Therefore it is speculated that occurrence of multiple axonal myelination in this model is a misguided regenerative response following partial denervation of unmyelinated fiber groups, implicating a defective Schwann cell axon interaction.

—V. P. Shetty, M.Sc., Ph.D.

*Research Officer*

—N. H. Antia, F.R.C.S.

*Trustee and Research Director  
The Foundation for Medical Research  
84-A, R. G. Thadani Marg.  
Worli  
Bombay 400018, India*

Reprint requests to Dr. Antia.

## REFERENCES

1. Brown, M. J. and Radich, S. J. Polyaxonal myelination in developing dystrophic and normal mouse nerves. *Muscle Nerve* 2 (1979) 217–220.
2. Okada, E., Mizuhira, V. and Nakamura, H. Abnormally combined myelinated and unmyelinated nerves in dystrophic mice. *J. Neurol. Sci.* 33 (1977) 243–249.
3. Shetty, V. P. and Antia, N. H. Myelination around multiple axons in the peripheral nerve. An unusual ultrastructural observation. *Acta Neuropathol.* 50 (1980) 147–151.
4. Shetty, V. P. and Antia, N. H. Degeneration and regeneration of unmyelinated fibers in experimental leprosy neuropathy. *Int. J. Lepr.* 49 (1981) 324–330.
5. Waxman, S. G. Peripheral nerve axon processes sharing a common myelin sheath. *Brain Res.* 7 (1968) 469–473.