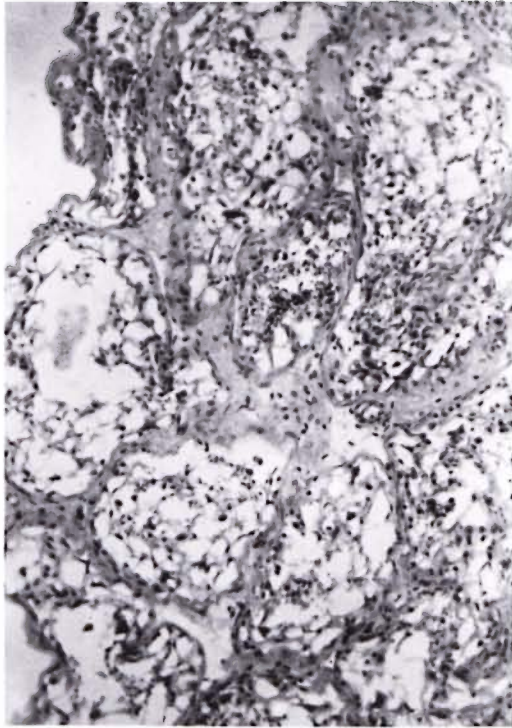


Testicular Biopsy in Antispermatozoal Antibody Positive Tuberculoid Leprosy Patients

TO THE EDITOR:

In an earlier study of antispermatozoal antibodies (ASA) in tuberculoid leprosy, 9 out of 33 cases were found to show ASA in their sera but in none of these cases was testicular biopsy possible (¹).

In the present communication, 24 male and 4 female tuberculoid patients were



THE FIGURE. Testicular atrophy in tuberculoid leprosy cells of the tubules show vacuolar degeneration (H & E $\times 100$).

studied for the presence of ASA. Anti-spermatozoal antibodies were demonstrated in 8 out of 24 male tuberculoid patients (33%) by sperm agglutination, immobilization and hemagglutination tests. None of the female tuberculoid cases showed evidence of ASA. The incidence of ASA in the male patients increased with the duration of the disease.

The tuberculoid patients who were ASA positive were subjected to testicular biopsy. These biopsies showed thickened basement membranes of the seminiferous tubules and vacuolar degeneration of the cells lining the tubules. There was no evidence of spermatogenesis. Interstitial cells were found to be increased (The Figure).

The exact mechanism of production of ASA in tuberculoid leprosy is not known since the testes are never affected clinically. In view of the atrophic changes observed in the testes, it is possible that there may be some cell-mediated tissue damage to the testes occurring in tuberculoid disease which results in the production of ASA.

—Suresh C. Gupta, M.D., F.R.C.P.

Department of Pathology

—Ashok K. Bajaj, M.D., F.I.C.A.

Department of Dermatology

—Premala A. Singh, M.D., D.C.P.

Department of Pathology

MLN Medical College

Allahabad (U.P.), India

REFERENCE

1. Gupta, S. C. A study of antispermatozoal antibodies in leprosy. *Int. J. Lepr.* **50** (1982) 43–46.