

## S-100 Protein and Immunoperoxidase Technique as an Aid in the Histopathologic Diagnosis of Leprosy<sup>1</sup>

Raul N. Fleury and Carlos E. Bacchi<sup>2</sup>

Histopathologic examination is important for the diagnosis, prognosis and evolutionary monitoring of leprosy. Histopathologic diagnosis usually is not difficult in the lepromatous and borderline types of the disease because of the abundance of bacilli in the lesions, but in the tuberculoid type (TL) and in the indeterminate group (IL) diagnosis is more difficult and frequently not feasible. In these cases, the detection of bacilli is very difficult in histologic sections stained by the Fite-Faraco technique or by other variations of the Ziehl-Neelsen technique. With respect to the polar tuberculoid type of leprosy (TT in the classification of Ridley and Jopling<sup>13</sup>), in 301 biopsies of tuberculoid leprosy (TL) cases performed at the Lauro de Souza Lima Hospital from 1980 to 1985, we detected 98 cases of positive bacilloscopy, usually after an exhaustive search on multiple sections according to the recommendations of Ridley<sup>12</sup>. Thus, a very high percentage of cases was left with negative bacilloscopy. This is also the experience of many other histopathologists<sup>(1, 4, 6, 12, 14)</sup>. The fact creates a serious diagnostic problem when one considers that many other skin diseases are manifested as tuberculoid granulomas which are frequently indistinguishable from those occurring in TL (sarcoidosis, skin tuberculosis, secondary syphilis, sarcoid forms of paracoccidioidomycosis, etc.)<sup>(1)</sup>.

The detection of impairment of cutaneous nerve branches by the inflammatory reactions permits the differential diagnosis of TL from other skin granulomatoses<sup>(1, 2, 4, 12, 14)</sup>. However, there are some difficulties in the visualization of nerve impair-

ment in histologic sections. For example: a) The simple involvement or even penetration of the perineurium by the inflammatory reaction can be observed in other pathologies such as lupus vulgaris, secondary syphilis, lichen planus and morphea<sup>(8)</sup>. b) The visualization of sections of skin nerve branches surrounded by granulomas does not necessarily imply a nerve lesion<sup>(12)</sup>. c) The total absence of nerve branches in a skin granulomatosis may indicate the presence of leprosy<sup>(12)</sup>, but this is difficult to evaluate because biopsies are not always of the appropriate size and because of the wide variation in the amount of skin nerve branches from one biopsy to another.

The data that more effectively show nerve damage in biopsies are: a) dense infiltration of inflammatory cells in the endoneurium, b) endoneural granulomas, c) identification of nerve branches inside the granulomas.

The inflammatory infiltrate or the granulomas often totally blot out the nerve structure, and the identification of nerve remains inside the granulomas in sections stained with hematoxylin and eosin (H&E) is not easy, since these remains are confused with epithelioid cells, fragments of arrector pili muscles, and small vessels at the periphery of the granulomas.

In an attempt to overcome these difficulties and to make it possible to diagnose TL in skin biopsies containing no bacilli and without obvious damage to nerve branches, we utilized the immunoperoxidase technique associated with S-100 protein as a nerve marker in routine sections.

S-100 protein is an acidic calcium-binding protein initially identified in the brain of several mammalian species and called S-100 because of its solubility in 100% ammonium sulfate<sup>(11)</sup>. More recently, S-100 protein has been detected by the immunoperoxidase technique in tissue of neurogenic and non-neurogenic origin, and the technique can also be used to visualize Schwann cells in peripheral nerves<sup>(9)</sup>. Thus, we ex-

<sup>1</sup> Received for publication on 16 June 1986; accepted for publication in revised form on 2 February 1987.

<sup>2</sup> R. N. Fleury, M.D., Hospital Lauro de Souza Lima, Rod. Bauru, Jau, KM 115, 17.100 Bauru, S.P., Brasil. C. E. Bacchi, M.D., Departamento de Patologia, Faculdade de Medicina de Botucatu-UNESP, 18.600 Botucatu, S.P., Brasil.

Reprint requests to Dr. Bacchi.

amed skin biopsies from patients suspected of having leprosy for S-100 protein using a sensitive immunoperoxidase reaction in order to detect peripheral nerve lesions that may permit the diagnosis of leprosy.

#### MATERIALS AND METHODS

Two groups of biopsies were selected: Group 1 = 9 biopsies of patients within the tuberculoid range of leprosy. Five of these were polar tuberculoid cases (TL), 3 were reactive tuberculoid cases (RT), and 1 was borderline (BT according to the classification of Ridley and Jopling<sup>13</sup>). Histopathologic diagnosis was possible because of the detection of bacilli on nerve branches, or because of obvious nerve branch alterations observed by the H&E technique or even by the Fite-Faraco technique. Group 2 = 9 biopsies from patients with a clinical diagnosis of TL not confirmed by histopathology because of the absence of bacilli and/or nerve lesions. All of the biopsies from both groups were treated with the immunoperoxidase technique, peroxidase anti-peroxidase system (PAP), for S-100 protein detection and possible nerve visualization.

**Immunoperoxidase staining.** Paraffin blocks were cut into 4  $\mu$ m sections, deparaffinized with xylene and rehydrated in graded ethanol concentrations to distilled water. The slides were treated with 3% hydrogen peroxide for 5 min to block endogenous peroxidase, and further washed in distilled water and phosphate-buffered saline (PBS), pH 7.3. Ten percent normal swine serum (Dakopatts) was applied for 20 min at 37°C, followed by two washes in PBS. All further incubations were at 37°C in a humidified chamber. The primary antiserum, anti-S-100 protein antibody (Dakopatts), was applied at a 1:500 dilution for 30 min followed by swine anti-rabbit immunoglobulin antiserum (Dakopatts) at a 1:20 dilution. The sections were washed with PBS, incubated with a rabbit peroxidase anti-peroxidase complex (Dakopatts) at a 1:30 dilution for 30 min, and treated with fresh 3'-diaminobenzidine (Sigma) in 0.05 M Tris-HCl, pH 7.6, activated with hydrogen peroxide for 5 min to visualize the brown color indicating peroxidase activity. Harris' hematoxylin was used as a counterstain, af-

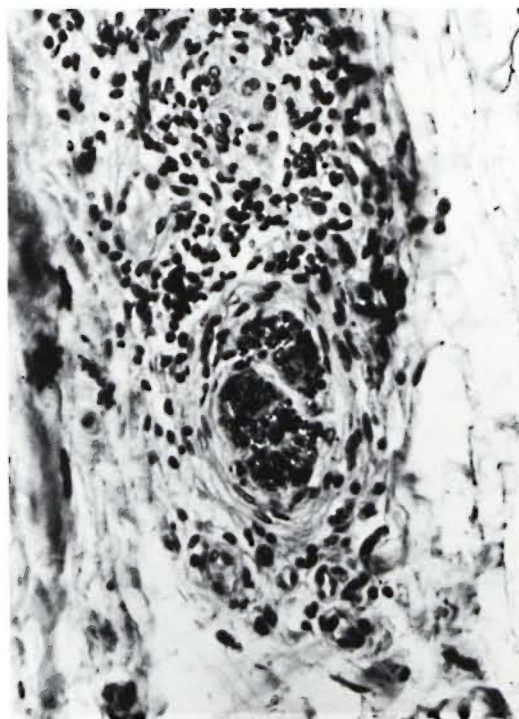


FIG. 1. Case 6, group 1 = tuberculoid leprosy (TL). Cutaneous nerve at periphery of a granuloma positive for S-100 protein. Note thickened perineurium (peroxidase anti-peroxidase [PAP]  $\times 100$ ).

ter which the sections were dehydrated in graded ethanol concentrations, cleared in xylene, and mounted in Permount®. Normal rabbit serum was used at a 1:500 dilution as a negative control, and a melanoma biopsy stained for S-100 protein was used as a positive control.

Both the slides stained with H&E and Fite-Faraco and the slides treated by the immunoperoxidase technique for S-100 protein were examined with emphasis on the morphological evaluation of cutaneous nerve branches.

#### RESULTS AND DISCUSSION

The results are shown in Tables 1 and 2. When evaluating the cutaneous nerves by H&E staining, we considered all of the alterations commonly observed and reported in the literature (<sup>4, 12</sup>). We also included an analysis of the conditions of the small branches of the superficial dermis, and recorded the finding of preserved nerve branches in the remainder of the dermis,

TABLE 1. *Alterations of cutaneous nerve branches in biopsies from patients with the*

Case Diagnosis	Case 1 BT <sup>a</sup>		Case 2 TL <sup>b</sup>		Case 3 RT <sup>c</sup>	
	H&E <sup>d</sup>	S-100	H&E	S-100	H&E	S-100
Histological techniques						
Preservation of superficial nerves	—	+	—	—	—	—
Nerves of the middle and deep dermis and subcutaneous						
Isolated and preserved	+	+	—	+	—	—
Preserved in the granulomas	+	+	—	+	—	+
Laminated perineurium	—	—	—	—	+	—
Perineural proliferation	+	—	—	—	—	—
Perineural infiltration	+	—	—	—	+	—
Endoneural infiltration	+	—	—	—	+	—
Endoneural granuloma	+	—	—	—	—	—
Nerve dissociation and fragmentation	—	+	+	+	—	—
Minimal nerve fragments	—	+	—	+	—	—
Bacilloscopy						
Granuloma		+		+		++
Nerves		+		+		++

<sup>a</sup> BT = borderline tuberculoid leprosy.<sup>b</sup> TL = polar tuberculoid leprosy.<sup>c</sup> RT = reaction tuberculoid leprosy.<sup>d</sup> H&E = hematoxylin and eosin stain.

both when isolated and when inside a granuloma.

S-100 protein was observed in the dendritic cells of the epidermis (melanocytes and Langerhans' cells), in the Langerhans' cells of the internal part of the granulomas and, at times, in the epithelial cells of sudoriparous adenomeres. Preserved nerve

branches acquired the strong dark colorations which delineate nerve fibers. The morphology of the nerve branches (<sup>3</sup>) was seen perfectly in both transverse and longitudinal nerve sections (Fig. 1). Also, the small superficial branches are much more easily distinguished than in routine slides with H&E.

TABLE 2. *Alterations of cutaneous nerve branches in biopsies from patients with clinical*

Case Diagnosis	Case 1 TL <sup>a</sup>		Case 2 TL		Case 3 TL	
	H&E <sup>b</sup>	S-100	H&E	S-100	H&E	S-100
Histological techniques						
Preservation of superficial nerves	—	—	—	+	—	+
Nerves of the middle and deep dermis and subcutaneous						
Isolated and preserved	—	—	—	—	—	+
Preserved in the granulomas	+	+	+	+	+	+
Laminated perineurium	—	—	—	—	—	—
Perineural proliferation	—	—	—	—	—	—
Perineural infiltration	+	+	—	—	—	—
Endoneural granuloma	—	—	—	—	—	—
Nerve dissociation and fragmentation	—	+	—	+	—	+
Minimal nerve fragments	—	—	—	—	—	—
Bacilloscopy						
Granuloma		—		—		—
Nerves		—		—		—

<sup>a</sup> TL = polar tuberculoid leprosy.<sup>b</sup> H&E = hematoxylin and eosin stain.



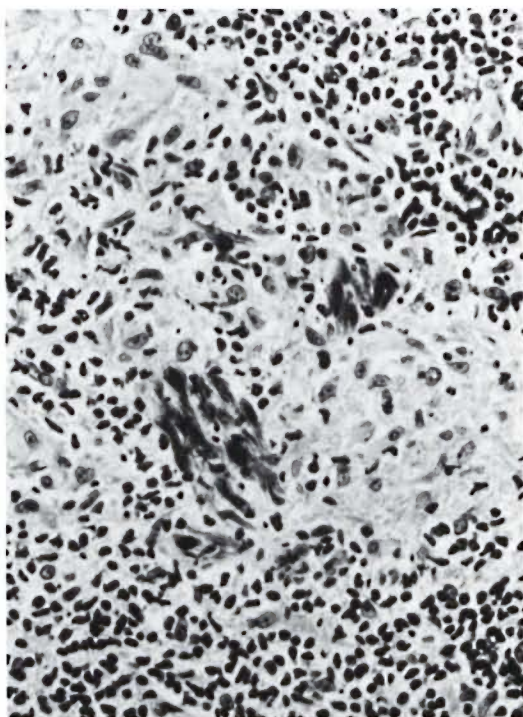


FIG. 2. Case 1, group 1 = tuberculoid leprosy (TL). Remains of cutaneous nerve branches inside a granuloma detected by S-100 protein (PAP  $\times 100$ ).

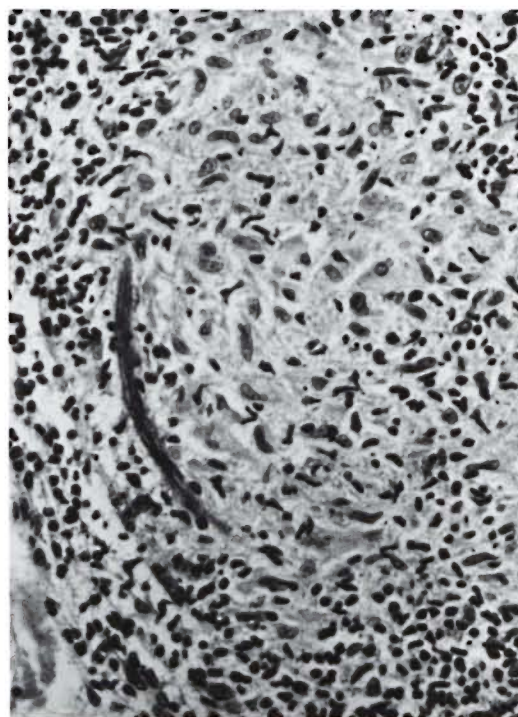


FIG. 3. Case 2, group 1 = tuberculoid leprosy (TL). Longitudinal segments of a cutaneous nerve branch inside a granuloma detected by S-100 protein (PAP  $\times 100$ ).

nique, biopsies from patients already diagnosed as having leprosy presented the severe nerve alterations typical of the manifestation of the tuberculoid forms of the disease (TL, RT, BT), with the exception of case 3. In some cases the technique also permitted the identification of preserved superficial nerve branches, and in almost all cases, preserved deep nerve branches either isolated or inside the granulomas.

We did not use the immunoperoxidase technique to identify alterations such as perineural proliferation, infiltration of the perineurium and endoneurium by inflammatory cells and endoneural granulomas because these alterations can be detected better in sections stained with H&E.

Table 2 shows that of all the cases considered compatible with TL by anatomoclinical correlation, eight were confirmed to have TL on the basis of the nerve alterations observed on slides treated by the S-100 immunoperoxidase technique, i.e., remains of dissociated and fragmented nerve branches and/or minimal nerve fragment still mor-

phologically recognizable. Only one patient (case 5, group 2) showed none of the above changes, but in all of the sections stained for S-100 protein there was total absence of nerve branches.

The data obtained in the present study show that use of the immunoperoxidase technique for the detection of S-100 protein to visualize peripheral nerves represents an efficient auxiliary aid in the diagnosis of tuberculoid leprosy. The use of this technique requires familiarity with the identification of the fragmented nerve structures in granulomas, which should pose no problem for experienced pathologists. Furthermore, the easy detection of superficial and deep nerve branches permitted by this technique opens an interesting field for more precise studies of the conditions of these structures in the various manifestations of leprosy.

#### SUMMARY

The histopathologic diagnosis of leprosy in the tuberculoid type (TL) and in the in-

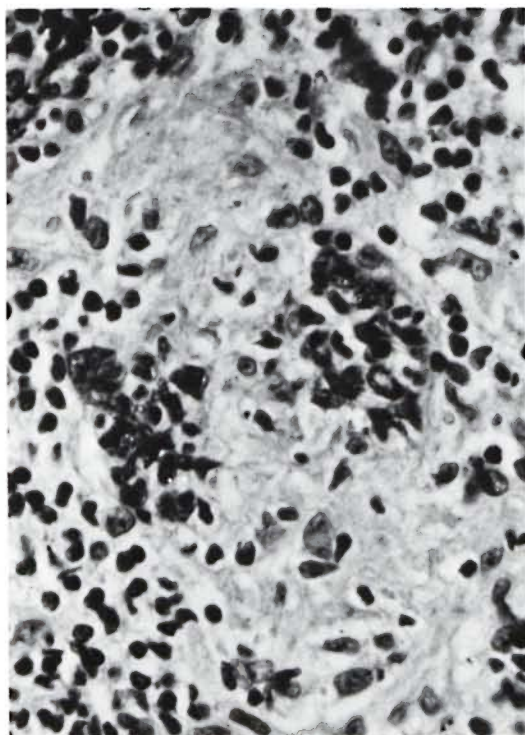


FIG. 4. Case 2, group 1 = tuberculoid leprosy (TL). Minimal transversal fragments of a cutaneous nerve branch inside a granuloma detected by S-100 protein (PAP  $\times 100$ ).

determinate group (IL) may be difficult and frequently unfeasible. The detection of the impairment of cutaneous nerve branches by the inflammatory reaction may permit the diagnosis of TL over other skin granulomas. In an attempt to overcome these diagnostic difficulties in the lesions with no bacilli and without obvious damage to nerve branches, we utilized the immunoperoxidase technique with S-100 protein as the nerve marker. Two groups were selected: Patients (group 1) with TL confirmed by the presence of bacilli, and patients (group 2) with a clinical diagnosis of TL not confirmed by histopathology. The slides treated by S-100 in group 2 showed that 8 cases (9 total) were confirmed to have TL on the basis of the nerve alteration observed by the immunoperoxidase technique. These data obtained in the present studies show that use of the immunoperoxidase technique for the detection of S-100 protein to visualize peripheral nerves represents an efficient auxiliary aid in the diagnosis of leprosy.

## RESUMEN

El diagnóstico histopatológico de la lepra en los tipos tuberculoide (LT) e indeterminado (LI) puede ser difícil y con frecuencia imposible. La detección de afectaciones de las ramas nerviosas cutáneas por la reacción inflamatoria puede permitir el diagnóstico diferencial de la LT sobre otros granulomas de la piel. En un intento de vencer las dificultades diagnósticas en las lesiones sin bacilos y sin obvio daño de las ramas nerviosas, se usó la técnica de la inmunoperoxidasa con la proteína S-100 como un marcador del tejido nervioso. Se seleccionaron 2 grupos: (1) pacientes con LT confirmada por la presencia de bacilos, y (2) pacientes con diagnóstico clínico de LT no confirmado por histopatología. Las secciones de tejido tratadas para proteína S-100 en el grupo (2) mostraron que en 8 casos (de un total de 9) se confirmó el diagnóstico de LT sobre la base de la alteración nerviosa observada por la técnica de la inmunoperoxidasa. Los resultados del presente estudio muestran que el uso de la técnica de la inmunoperoxidasa para la detección de la proteína S-100 en los nervios periféricos representa un auxiliar eficiente en el diagnóstico de la lepra.

## RÉSUMÉ

Le diagnostic histopathologique de la lèpre peut être malaisé dans le type tuberculoïde (TL) et dans le groupe indéterminé (IL); souvent, il ne peut pas être posé. La mise en évidence d'une perte de fonction des rameaux nerveux cutanés, suite à la réaction inflammatoire, peut permettre le diagnostic différentiel entre TL et d'autres granulômes cutanés. Dans le but de surmonter ces difficultés diagnostiques dans les lésions n'hébergeant pas de bacilles et ne présentant pas de lésions évidentes au niveau des rameaux nerveux, on a utilisé la technique par l'immunoperoxydase, avec la protéine S-100, comme marqueur des nerfs. On a choisi deux groupes. Le premier groupe consistait en malades atteints du type TL de la lèpre, confirmé par la présence de bacilles; le second groupe comprenait des malades chez lesquels le diagnostic clinique de TL n'avait pas été confirmé par l'anatomie pathologique. Après traitement par la protéine S-100, les frottis prélevés chez les malades du second groupe ont montré que 8 cas, sur un total de 9, souffraient effectivement du type TL, telles qu'en témoignaient les altérations nerveuses révélées par la technique à l'immunoperoxydase. Les données recueillies dans cette étude montrent dès lors que l'utilisation de la technique à la peroxydase pour la détection de la protéine S-100, en vue de rendre visible les nerfs périphériques, constitue un appoint efficace pour le diagnostic de la lèpre.

## REFERENCES

1. ACKERMAN, A. B. *Histologic Diagnosis of Inflammatory Skin Diseases*. Philadelphia: Lea & Febiger, 1978, p. 402.

2. ALAYON, F. L. and RATH DE SOUZA, P. Histologia patologica da lepra tuberculoide. Rev. Bras. Leprol. 8 Special Issue (1940) 225-233.
3. ASBURY, A. K. and JOHNSON, P. C. *Pathology of Peripheral Nerves*. Philadelphia: W. B. Saunders Company, 1978, pp. 34-39.
4. BINFORD, C. H. and MEYERS, W. M. Diseases caused by mycobacteria. In: *Pathology of Tropical and Extraordinary Diseases*. Binford, C. H. and Connor, D. H., eds. Washington, D.C.: Armed Forces Institute of Pathology, 1976, p. 214.
5. ENG, L. G., KOSES, J. C. and FORNO, L. Immunohistochemistry of brain protein in fixed paraffin-embedded tissue. Trans. Am. Soc. Neurochem. 7 (1976) 211.
6. FLEURY, R. N. Hanseniasis. In: *Dermatologia*. Silva, I. M. Rio de Janeiro: Livraria Atheneu, 1983, pp. 92-94.
7. HSU, S. M., RAINE, L. and FANGER, H. Use of avidin-biotin-peroxidase complex (ABC) in immunoperoxidase techniques: a comparison between ABC and unlabeled antibody (PAP) procedures. J. Histochem. Cytochem. 29 (1981) 557-580.
8. JACOB, M., CHACKO, C. J. G., ARUNTHATHI, S. and CHANDI, S. M. Significance and interpretation of nerve changes in skin biopsies when present in association with common dermatological conditions. Int. J. Lepr. 52 Suppl. (1984) 755.
9. KAHN, H. J., MARKS, A., THOM, H. and BAUMAL, R. Role of antibody to S-100 protein in diagnostic pathology. Am. J. Clin. Pathol. 79 (1983) 341-347.
10. KHANOLKAR, V. R. Pathology of leprosy. In: *Leprosy in Theory and Practice*. 2nd ed. Cochrane, R. G. and Davey, T. F., eds. Bristol: John Wright & Sons Ltd., 1969, pp. 136-139.
11. MOORE, B. W. A soluble protein characteristic of the nervous system. Biochem. Biophys. Res. Commun. 19 (1965) 739-744.
12. RIDLEY, D. S. *Skin Biopsy in Leprosy*. Basle: CIBA-GEIGY Ltd., 1977, p. 32.
13. RIDLEY, D. S. and JOPLING, W. H. Classification of leprosy according to immunity; a five-group system. Int. J. Lepr. 34 (1966) 255-273.
14. WEDDELL, G. Disorders of peripheral cutaneous nerves. J. Invest. Dermatol. 69 (1977) 130-135.